

AMERICAN BOARD OF GENERAL DENTISTRY

Example Case

**STANDARDIZED TREATMENT PLANNING
ORAL EXAMINATION**

Example Case Information

Chief Complaint:

“I have a gummy smile, my teeth look short.”

“I would like some of my back teeth replaced.”

Medical History:

The patient is a 51 year old female who reports a past medical history of hypertension (HTN), transient ischemic attack (TIA) due to thrombosis (2015), and gastroesophageal reflux disease (GERD). Past surgical history non-contributory. No known drug allergies (NKDA), but patient reports nausea/vomiting to codeine. Patient states a 40+ pack-year history of tobacco smoking and no alcohol consumption.

Dental History:

The patient states inconsistent dental treatment for the past 21 years, but now has available finances and time for comprehensive dental treatment. The patient desires treatment with the best long-term prognosis while also improving her esthetics.

Medications:

- Metoprolol 50mg
- Lisinopril 10mg
- Cimetidine 200mg
- Aspirin 81mg

Vital Signs:

- BP: 142/82
- Pulse: 72
- Respiration: 14
- Temperature: 97.6°F
- BMI: 31.5%

Example Case Information

Clinical Conditions: (Existing in Black, Caries in Red)

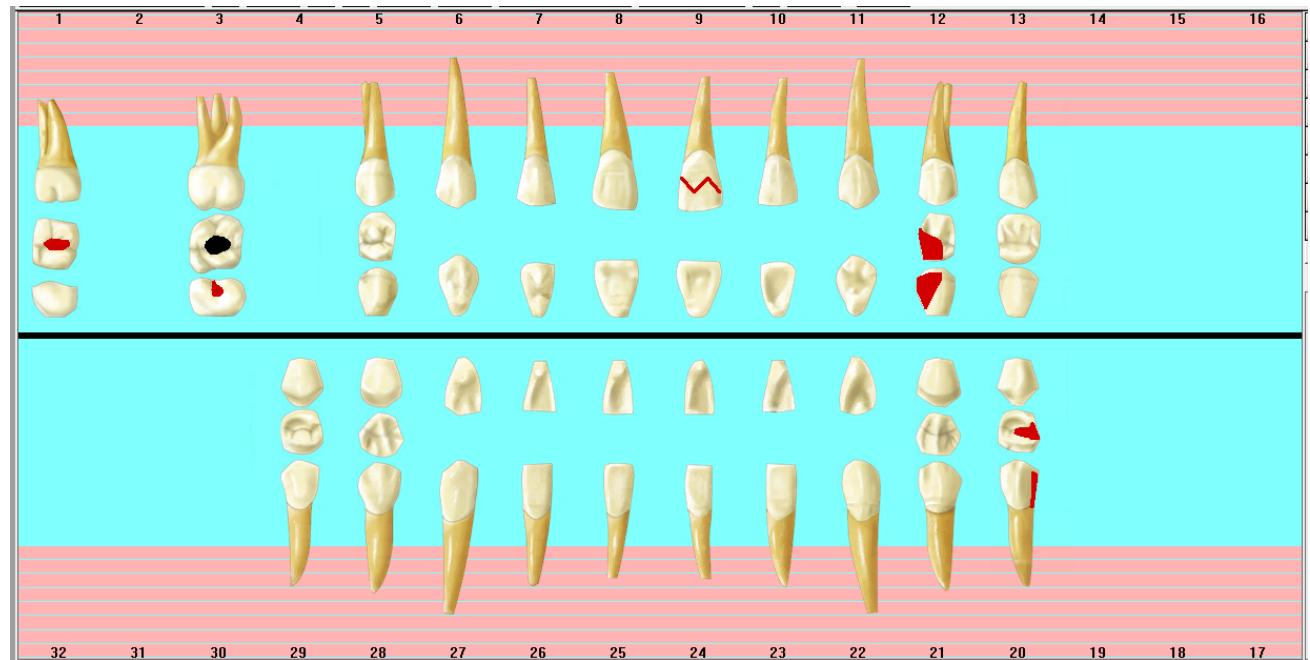
- Brushes 2x/day with a soft toothbrush, irregular flossing, no rinsing.
- No TMD; normal range of motion with maximal incisal opening 45mm.
- Articulation and occlusion: CR is not coincident with MIP; bilateral group function with anterior disclusion.

• Caries:

- #1 O
- #3 OL
- #12 MOL
- #20 DO

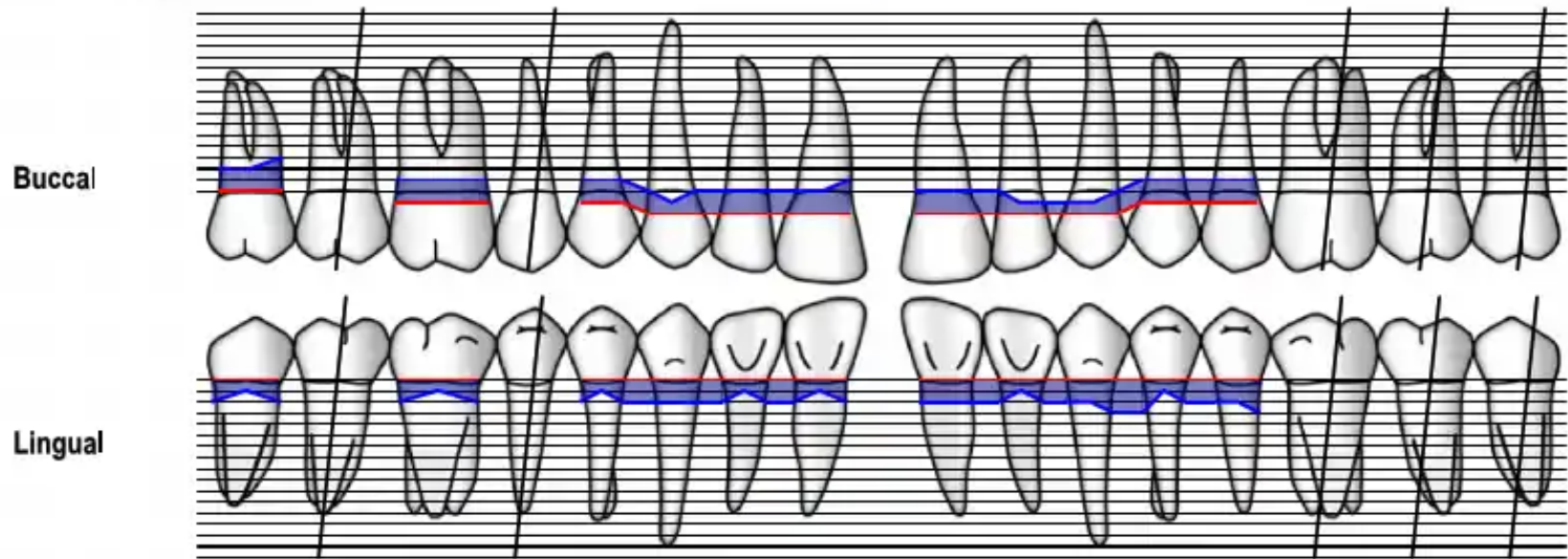
• Fractures:

- #9 I



- Cold response negative:
 - #12
- Percussion positive teeth
 - None

	18	17	16	15	14	13	12	11	21	22	23	24	25	26	27	28
Mobility	0		0		0	0	0	0	0	0	0	0	0			
Implant																
Furcation																
Bleeding on Probing	■ ■ ■					■ ■ ■	■ ■ ■	■ ■ ■	■ ■ ■	■ ■ ■	■ ■ ■	■ ■ ■	■ ■ ■			
Plaque	■ ■ ■						■ ■ ■	■ ■ ■					■ ■ ■			
Gingival Margin	0 0 0		1 1 1		1 1 1	2 2 2	2 2 2	2 2 2	2 2 2	2 2 2	2 2 2	1 1 1	1 1 1			
Probing Depth	2 2 3		2 2 2		2 2 2	2 1 2	2 2 2	2 2 3	2 2 2	2 1 1	1 1 2	2 2 2	2 2 2			



Gingival Margin	0 0 0		0 0 0		0 0 0	0 0 0	0 0 0	0 0 0	0 0 0	0 0 0	0 0 0	0 0 0	0 0 0			
Probing Depth	2 1 2		2 1 2		2 1 2	2 2 2	2 1 2	2 1 2	2 2 2	2 1 2	2 2 3	3 1 2	2 2 3			
Plaque	■ ■ ■				■ ■ ■	■ ■ ■						■ ■ ■	■ ■ ■			
Bleeding on Probing	■ ■ ■				■ ■ ■	■ ■ ■					■ ■ ■	■ ■ ■	■ ■ ■			
Furcation																
Note																

Mean Probing Depth = 1.7 mm

Mean Attachment Level = -1.1 mm

29% Plaque

36% Bleeding on Probing

Maxillary Periodontal Charting

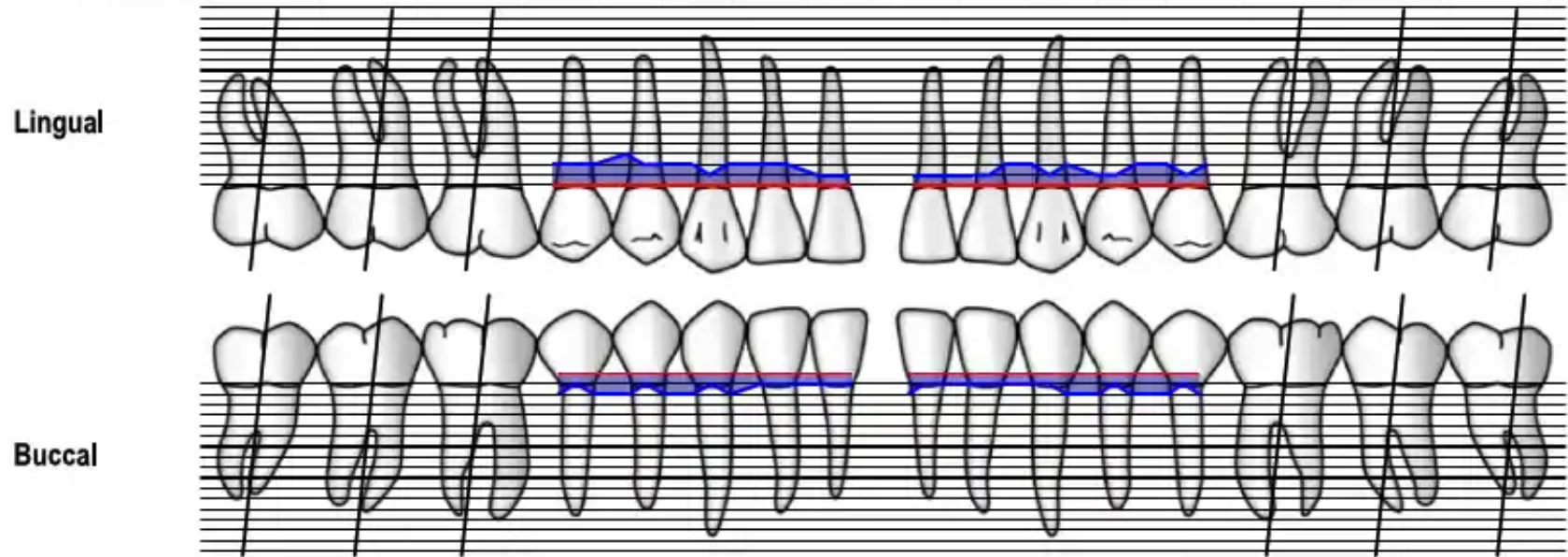
Mean Probing Depth = 1.7 mm

Mean Attachment Level = -1.1 mm

29 % Plaque

36 % Bleeding on Probing

Note																			
Furcation																			
Bleeding on Probing				■	■	■	■	■	■	■	■	■	■	■	■	■	■	■	■
Plaque			■	■	■	■	■	■	■	■	■	■	■	■	■	■	■	■	■
Gingival Margin			0	0	0	0	0	0	0	0	0	0	0	0	0	0	0	0	0
Probing Depth			2	2	2	3	2	2	2	1	2	2	2	2	1	1	1	1	1

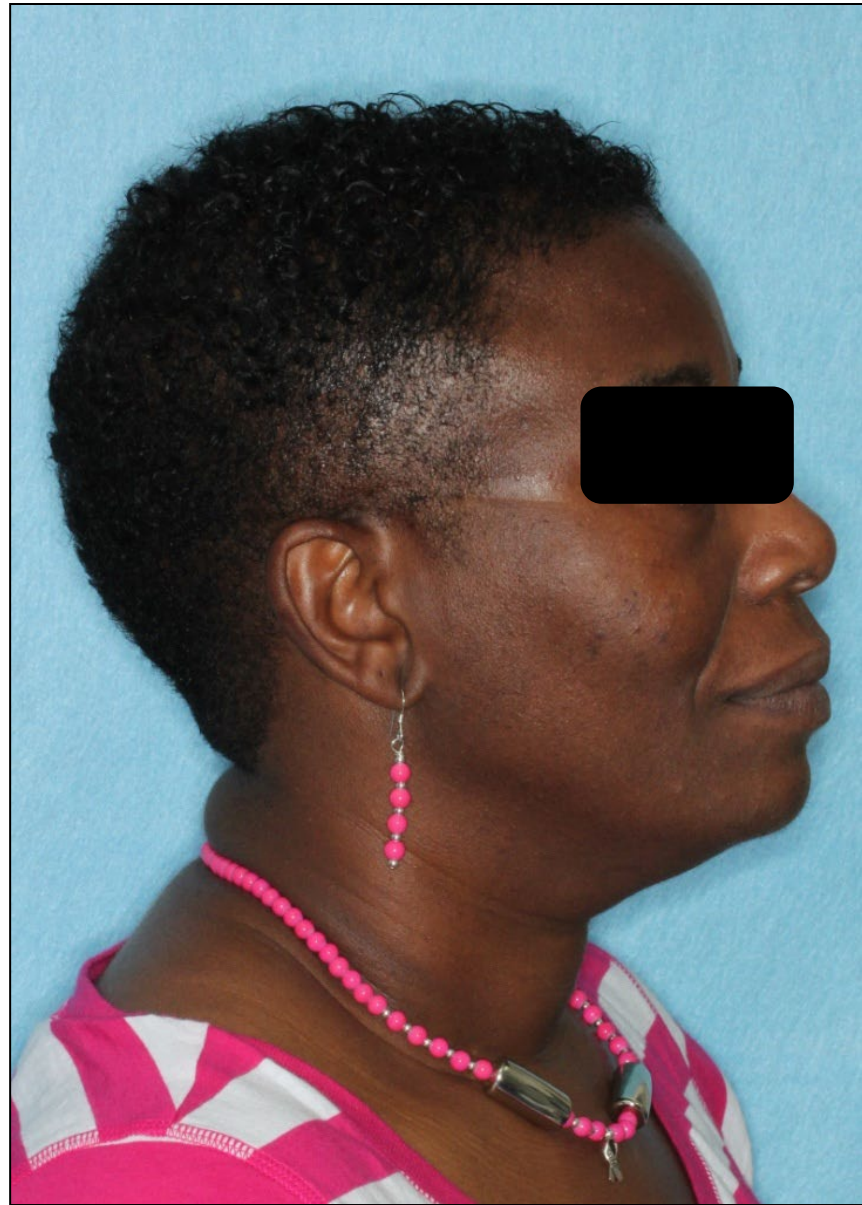

Gingival Margin			1	1	1	1	1	1	1	1	1	1	1	1	1	1	1	1	1
Probing Depth			2	1	2	2	1	2	1	1	1	1	1	1	1	1	1	1	1
Plaque			■						■				■	■	■			■	
Bleeding on Probing			■	■	■			■				■	■	■				■	
Furcation																			
Implant																			
Mobility			0	0	0	0	0	0	0	0	0	0	0	0	0	0	0	0	0

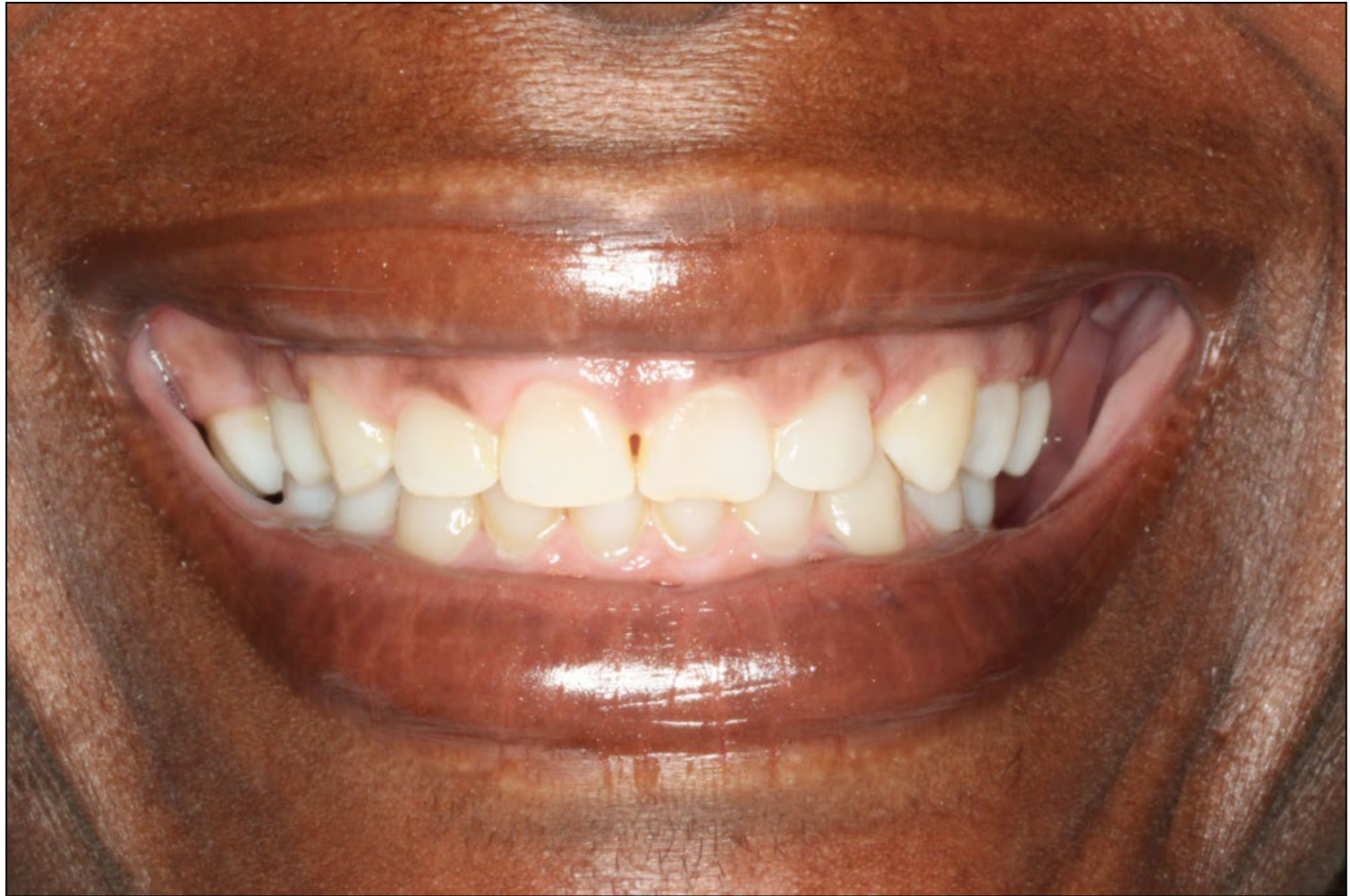Mandibular Periodontal Charting



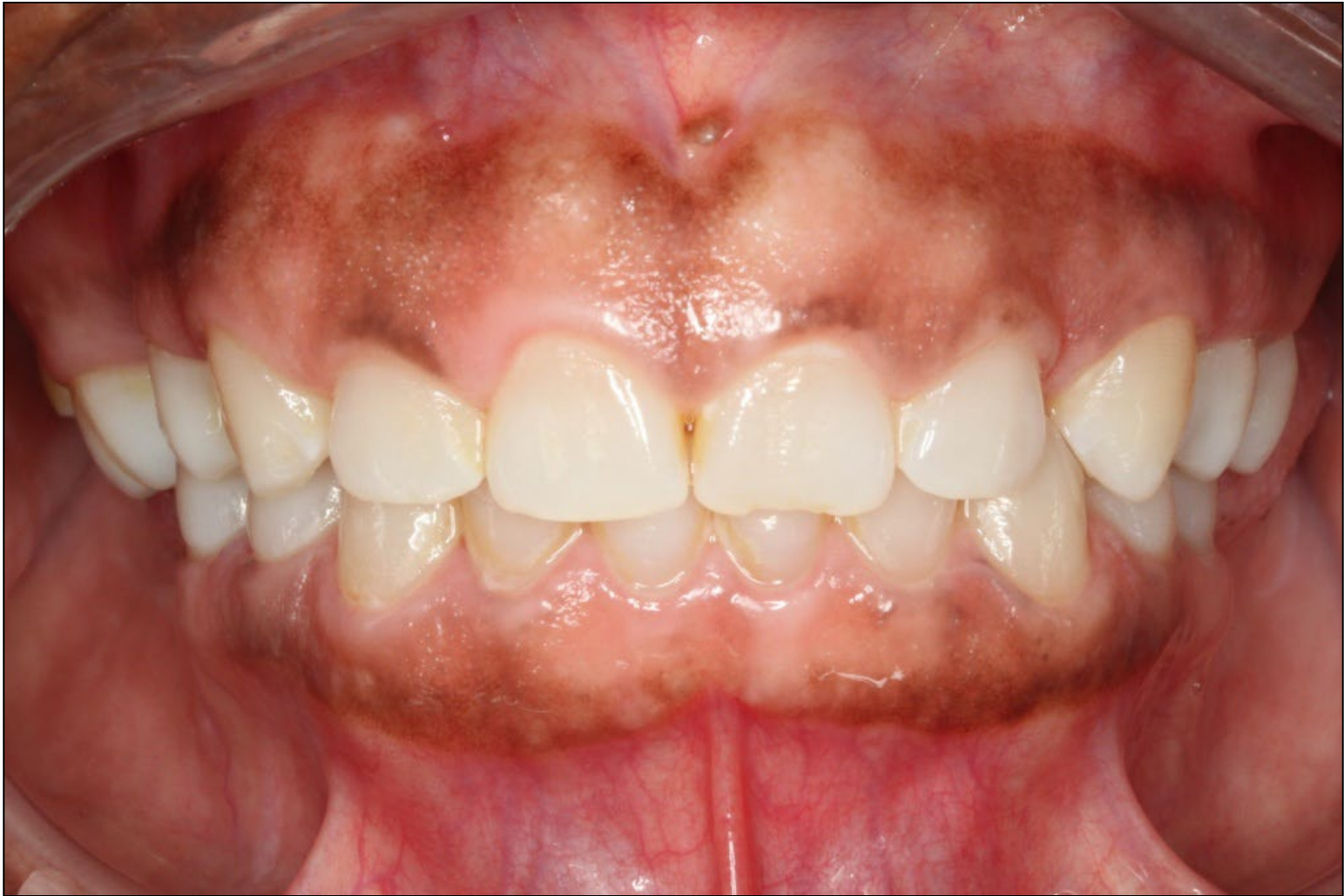FULL FACIAL/SMILE



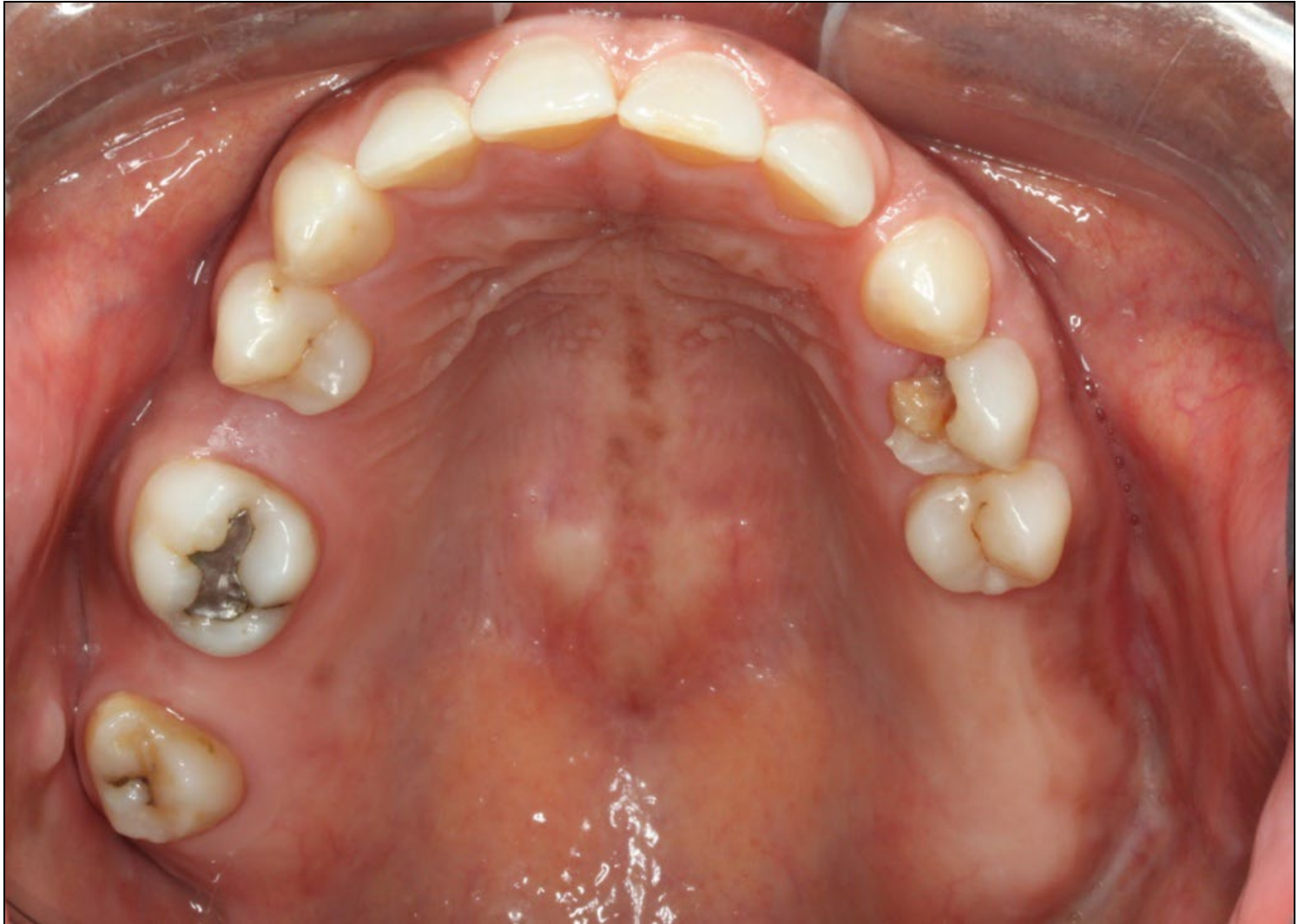PROFILE



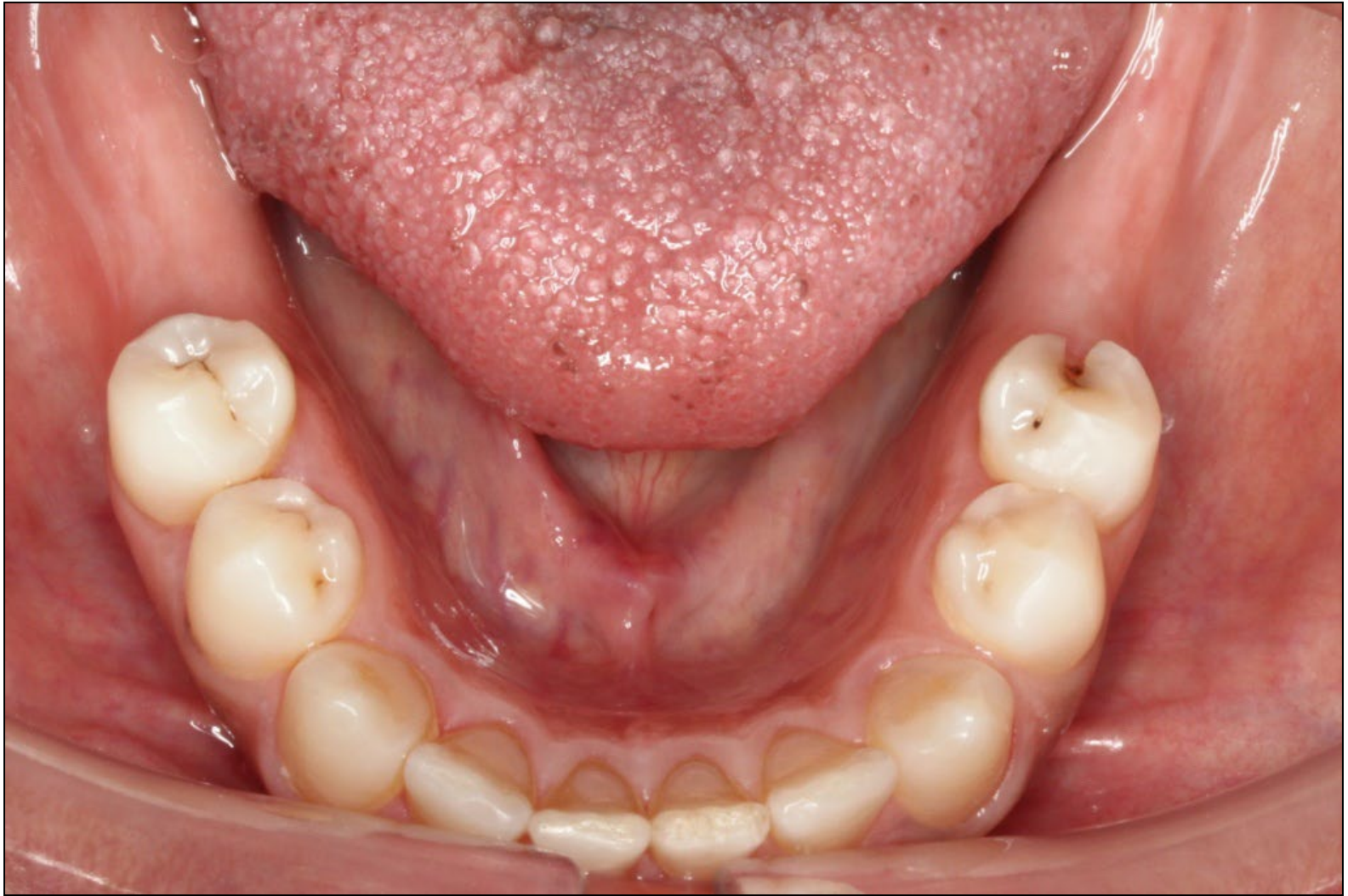SMILE



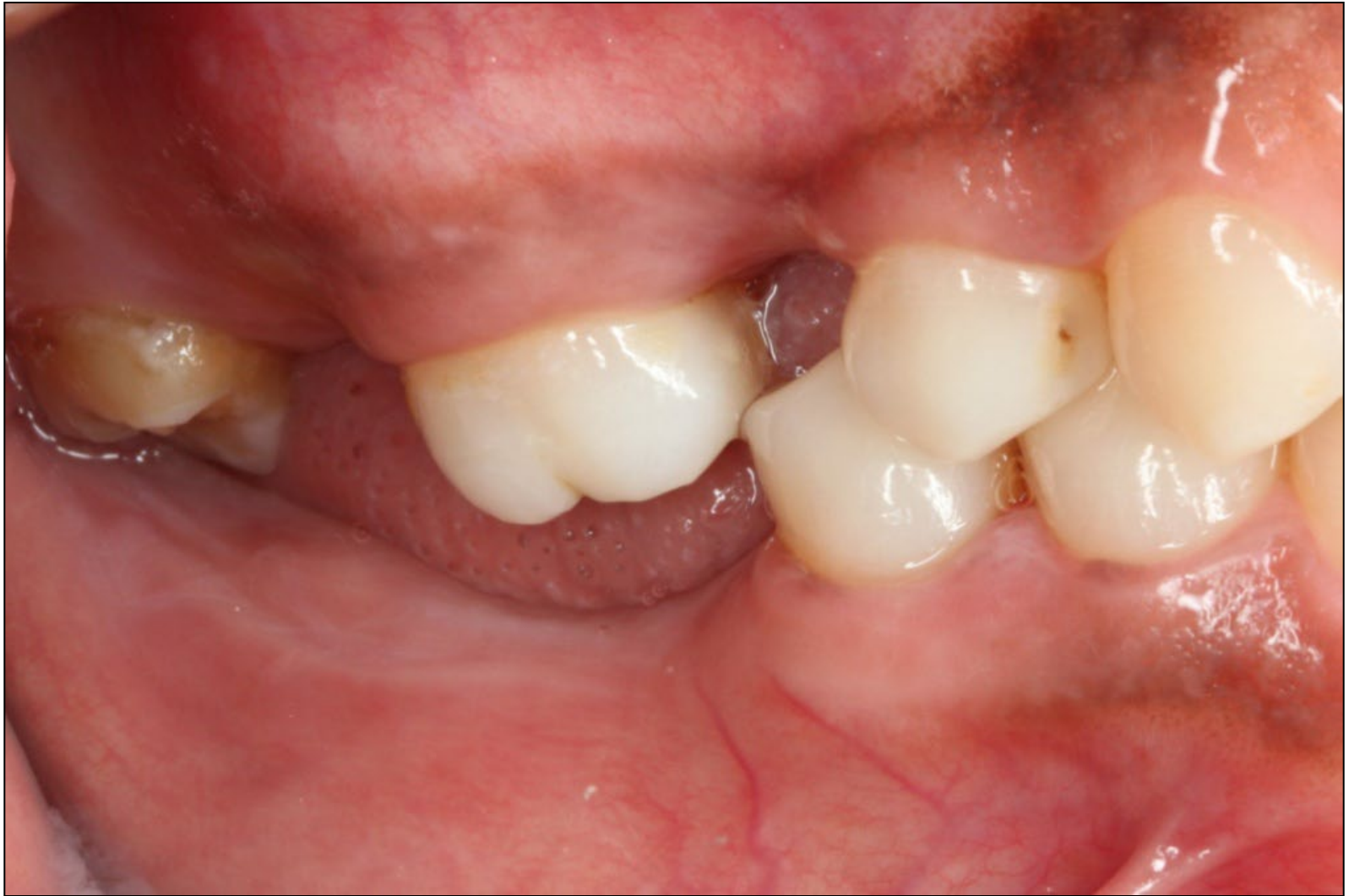Frontal View



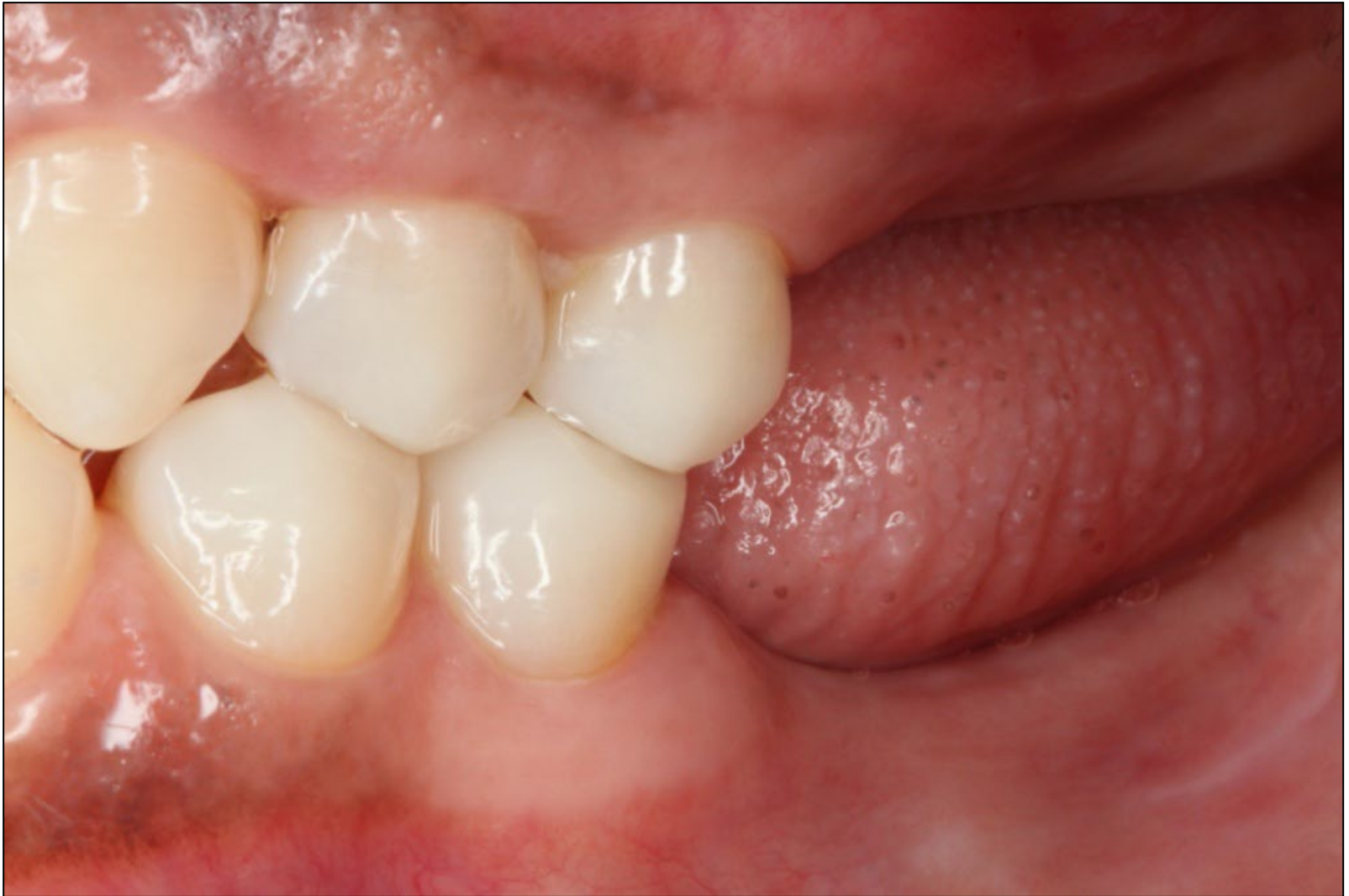Maxillary Occlusal View



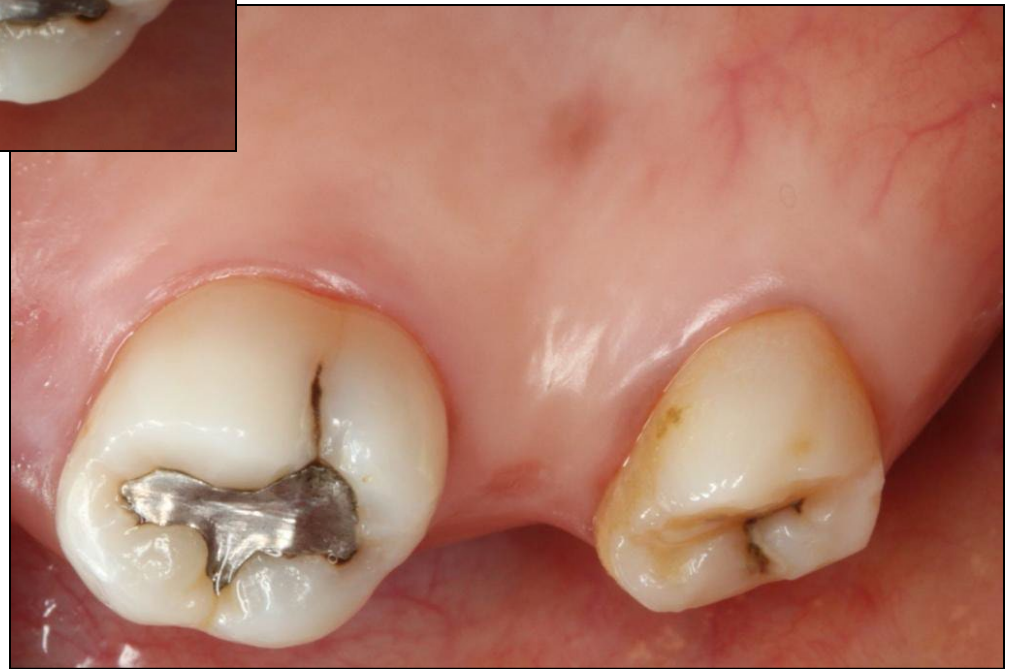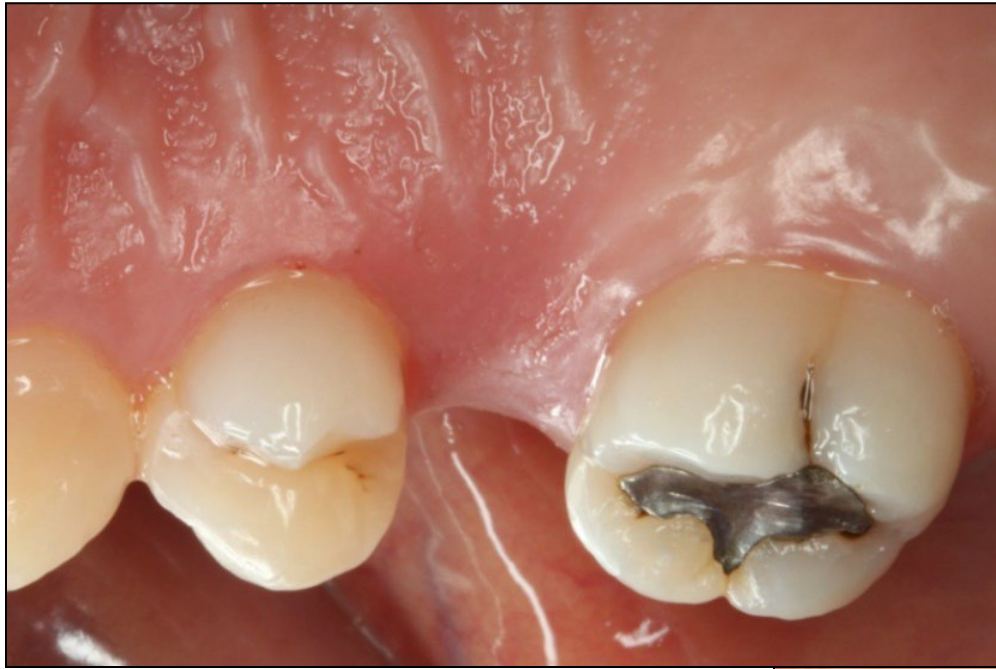Mandibular Occlusal View



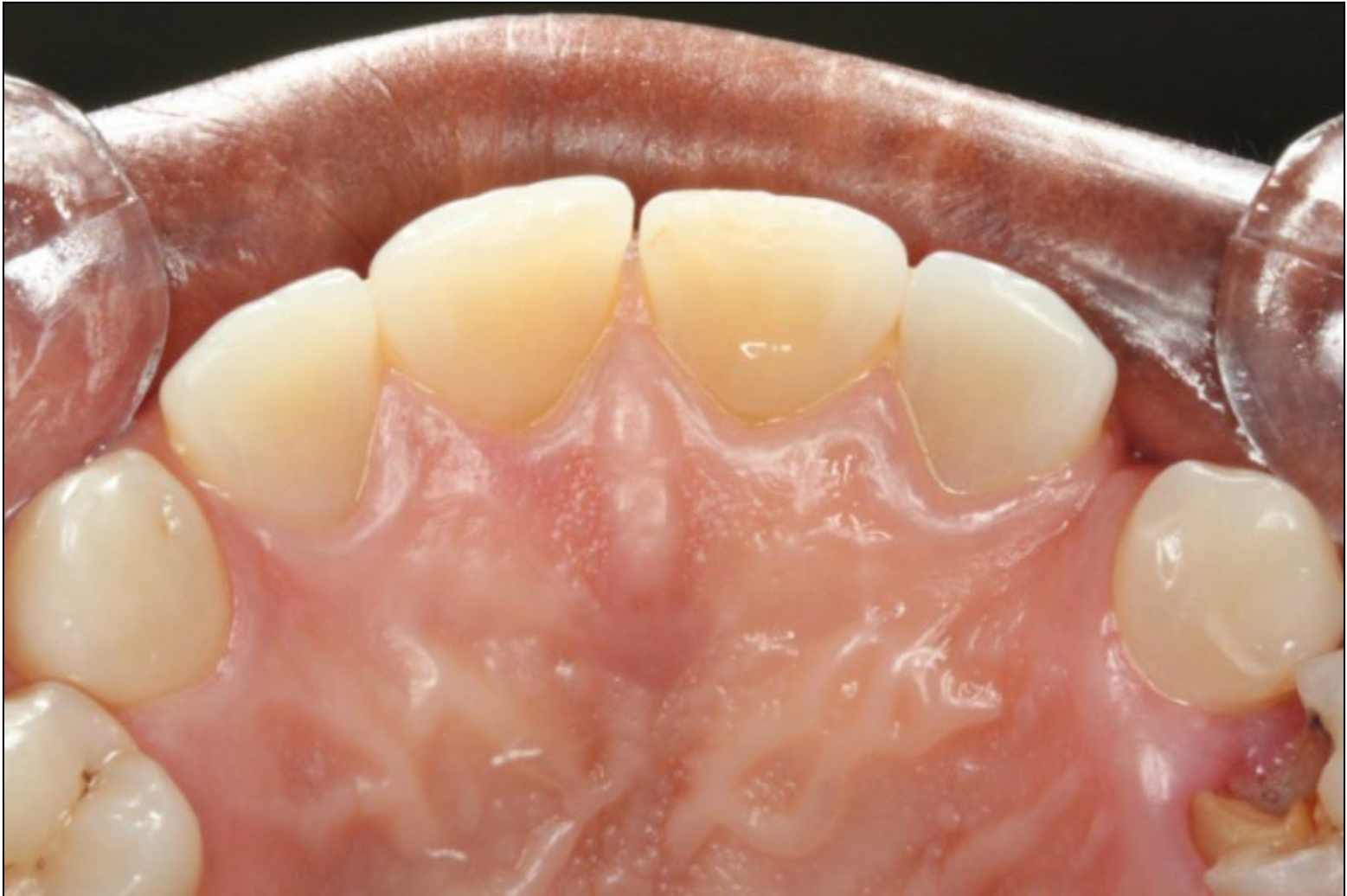Right Side in Occlusion



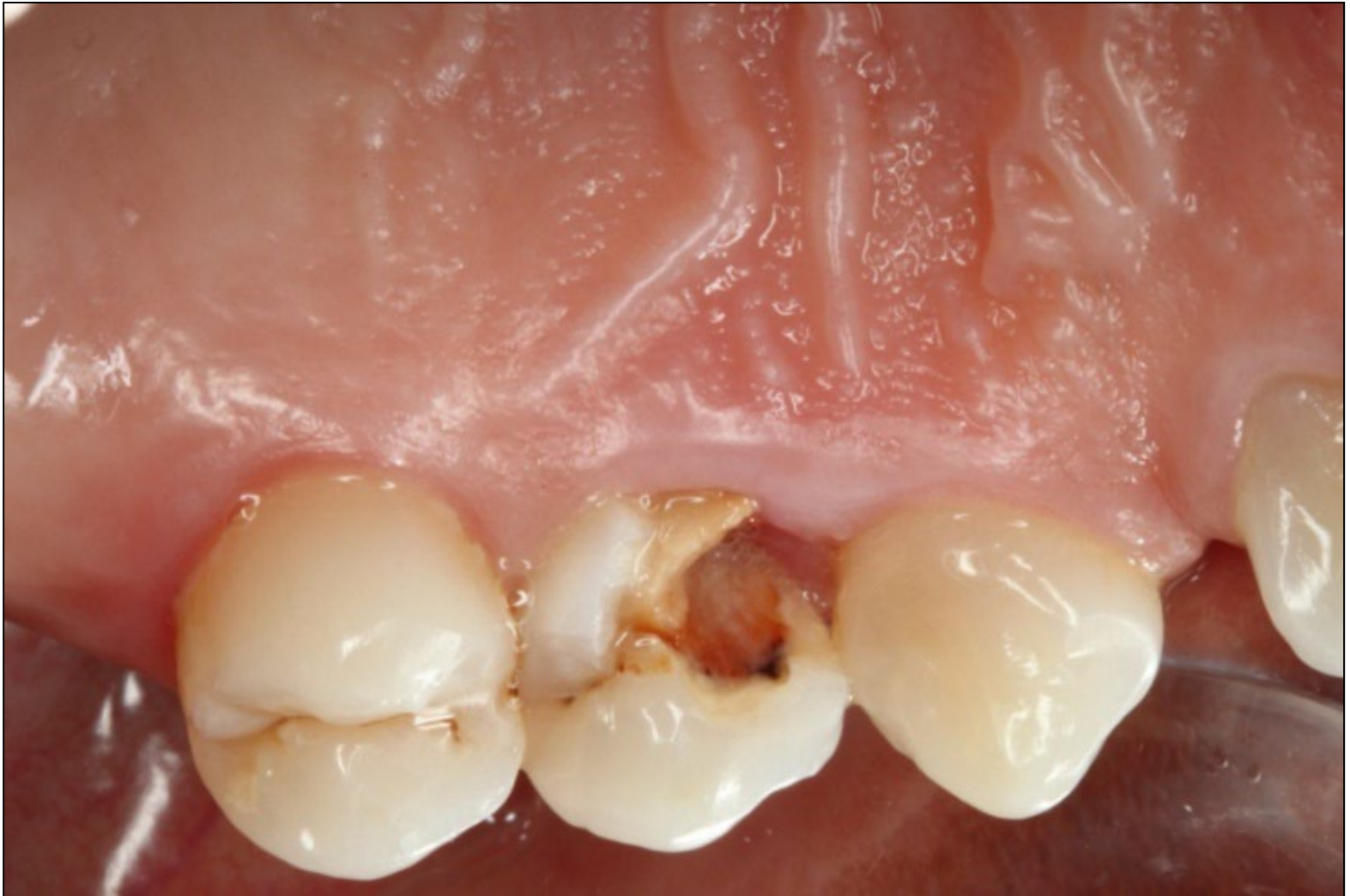Left Side in Occlusion



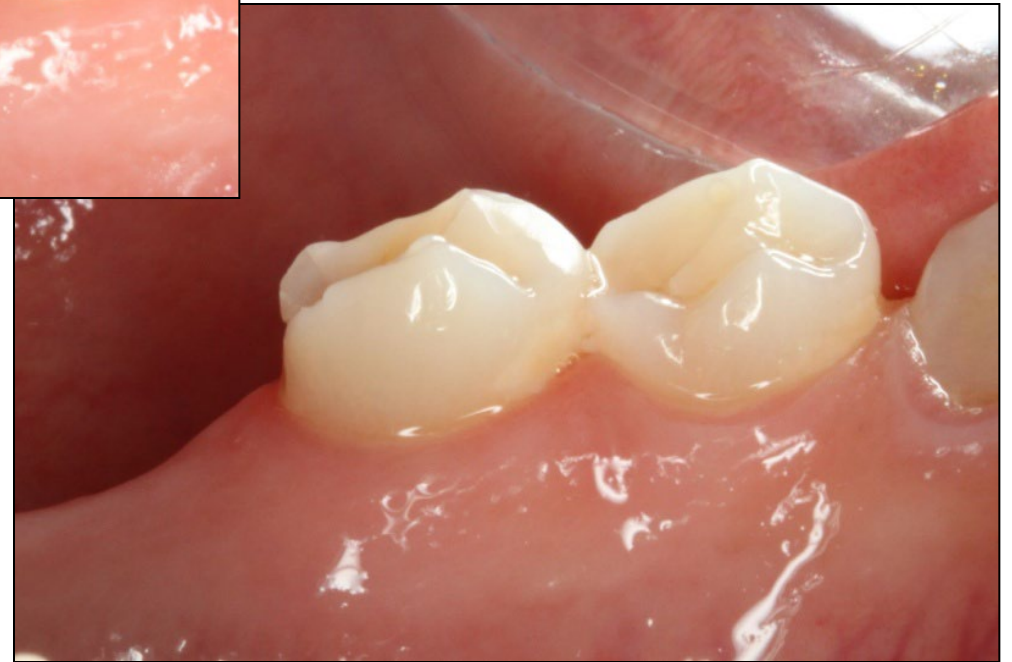
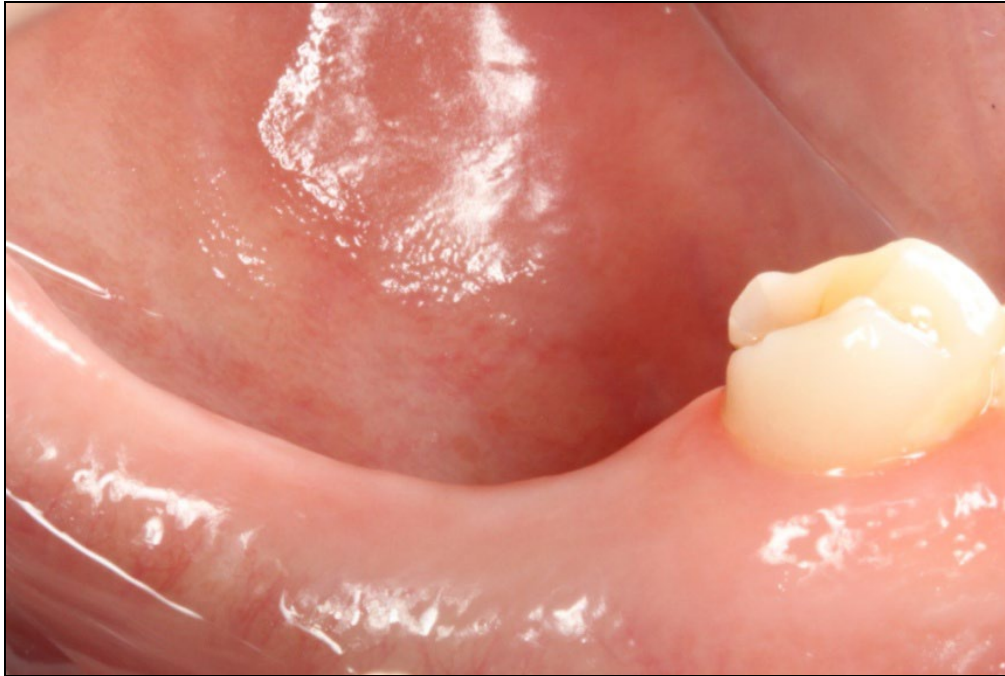
Maxillary Right Palatal View



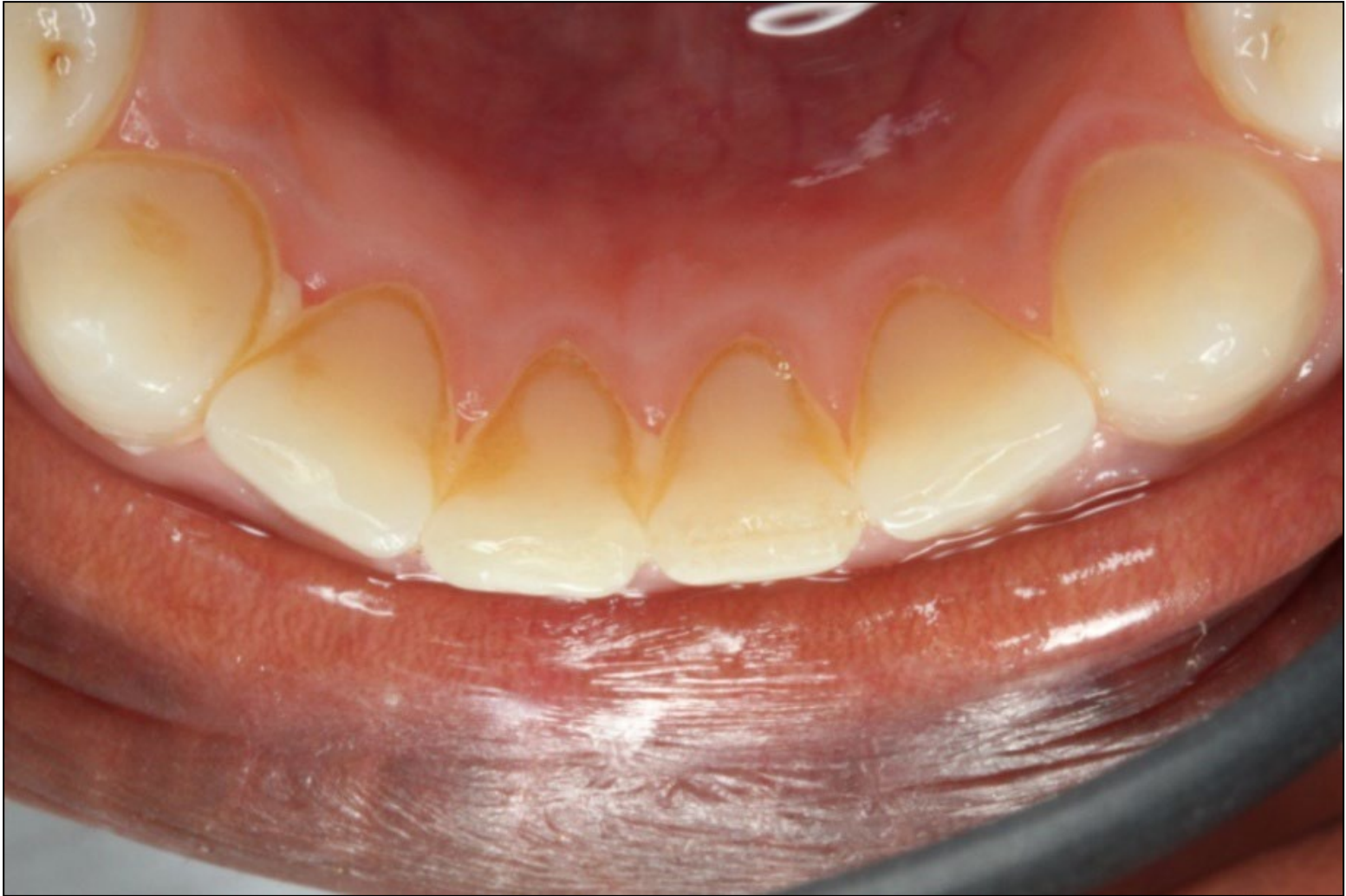Max Anterior Palatal View



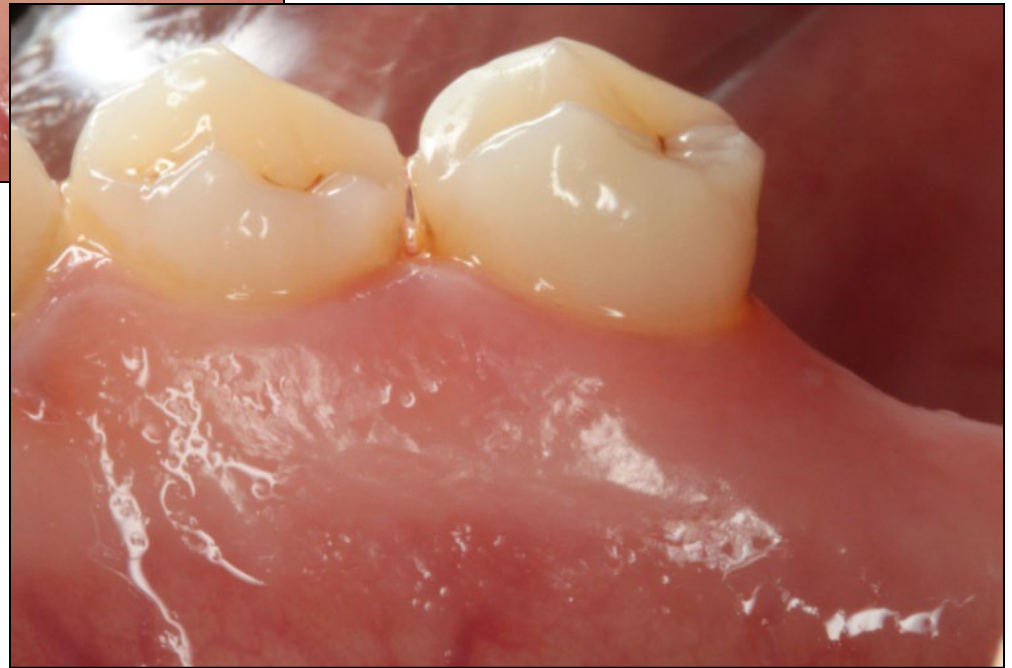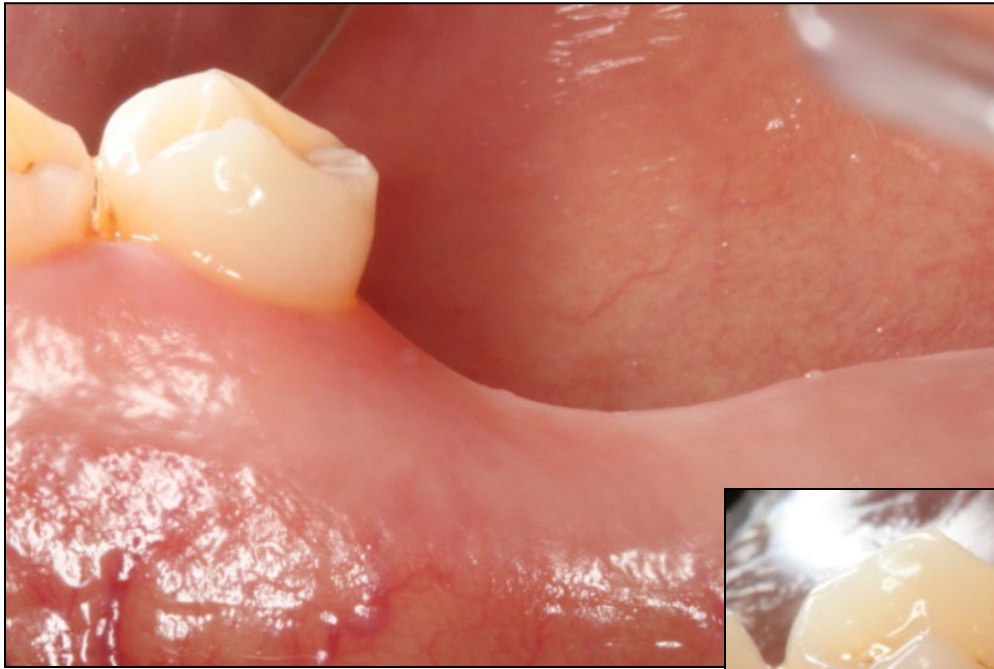Maxillary Left Palatal View



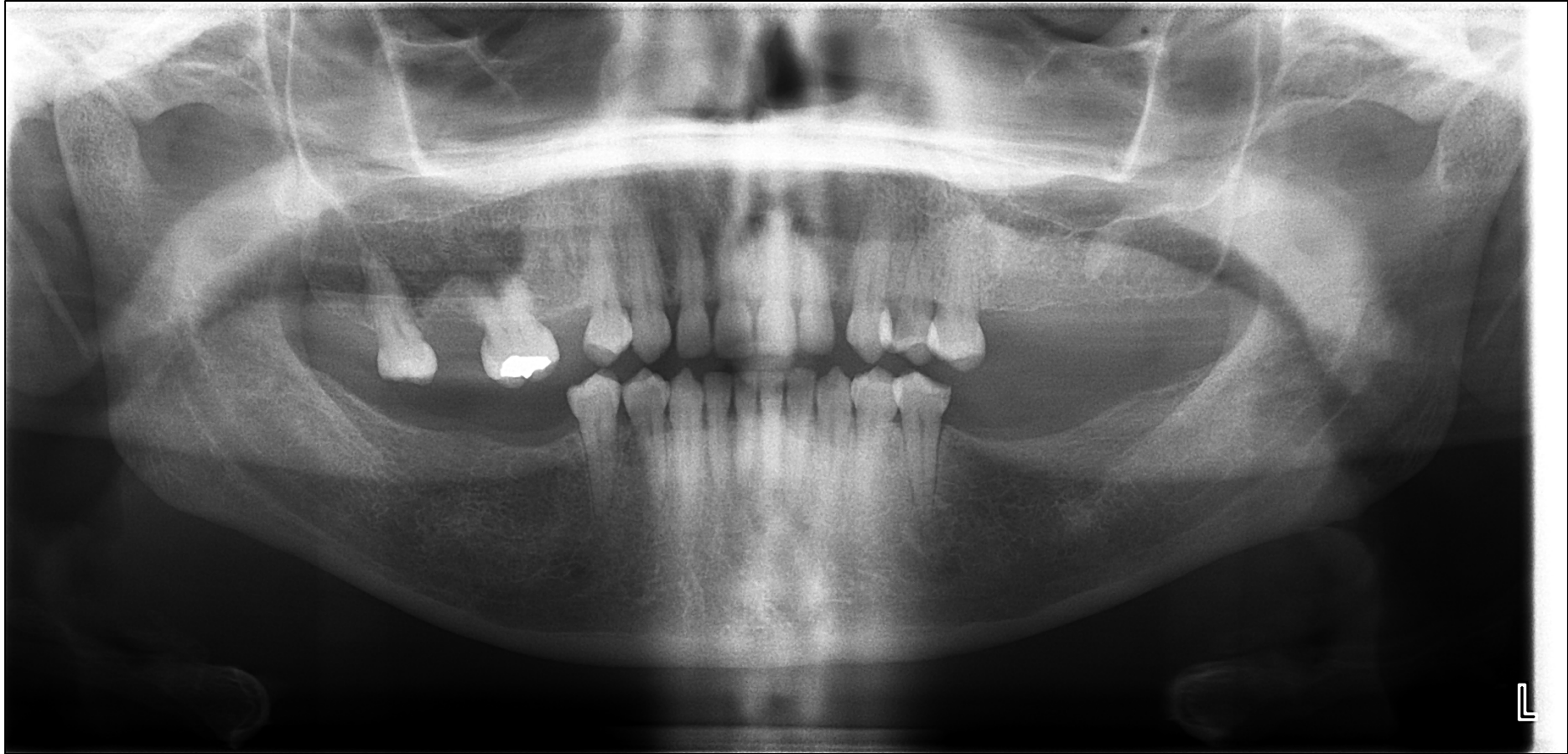
Mandibular Left Lingual View



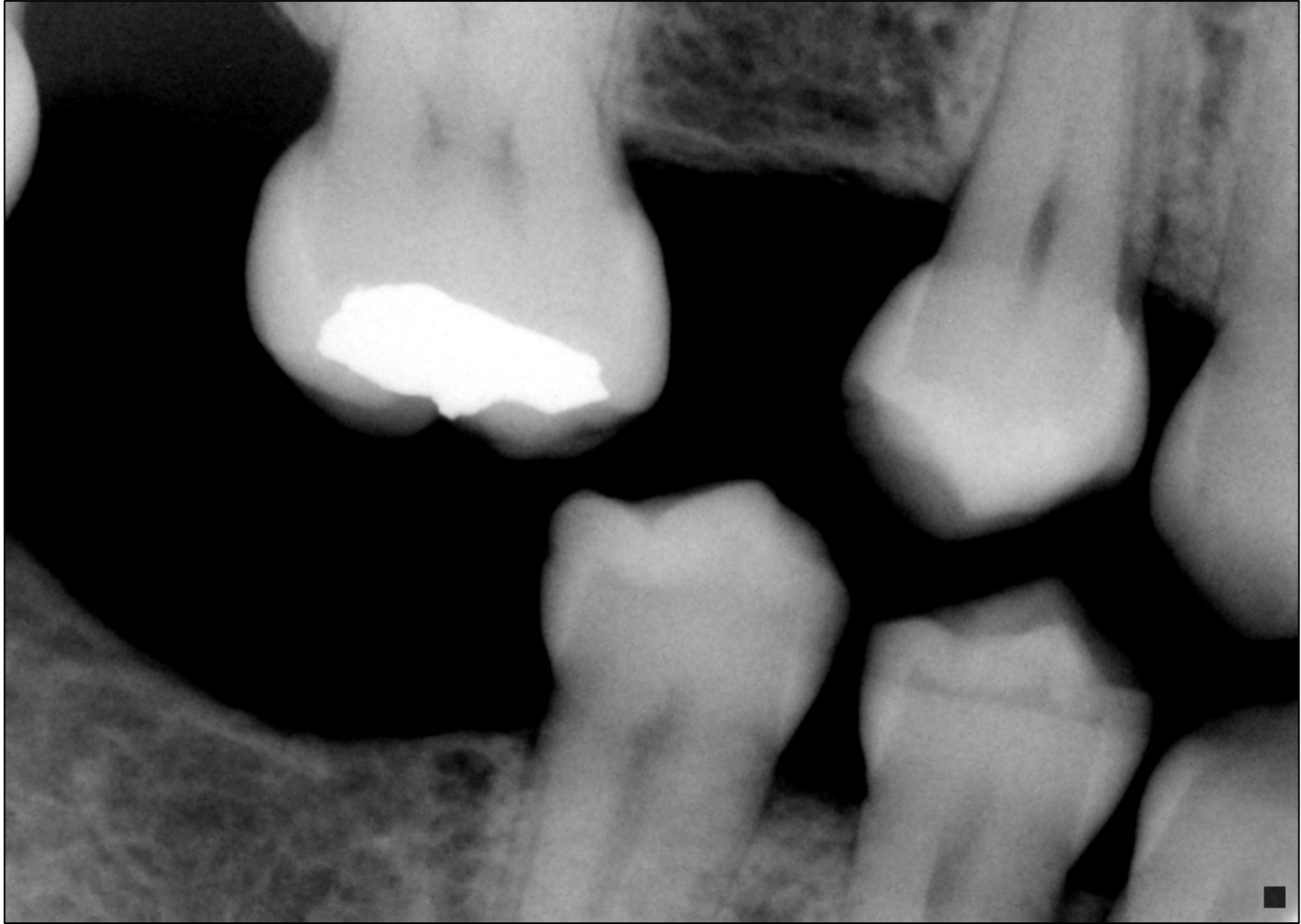Man Anterior Lingual View



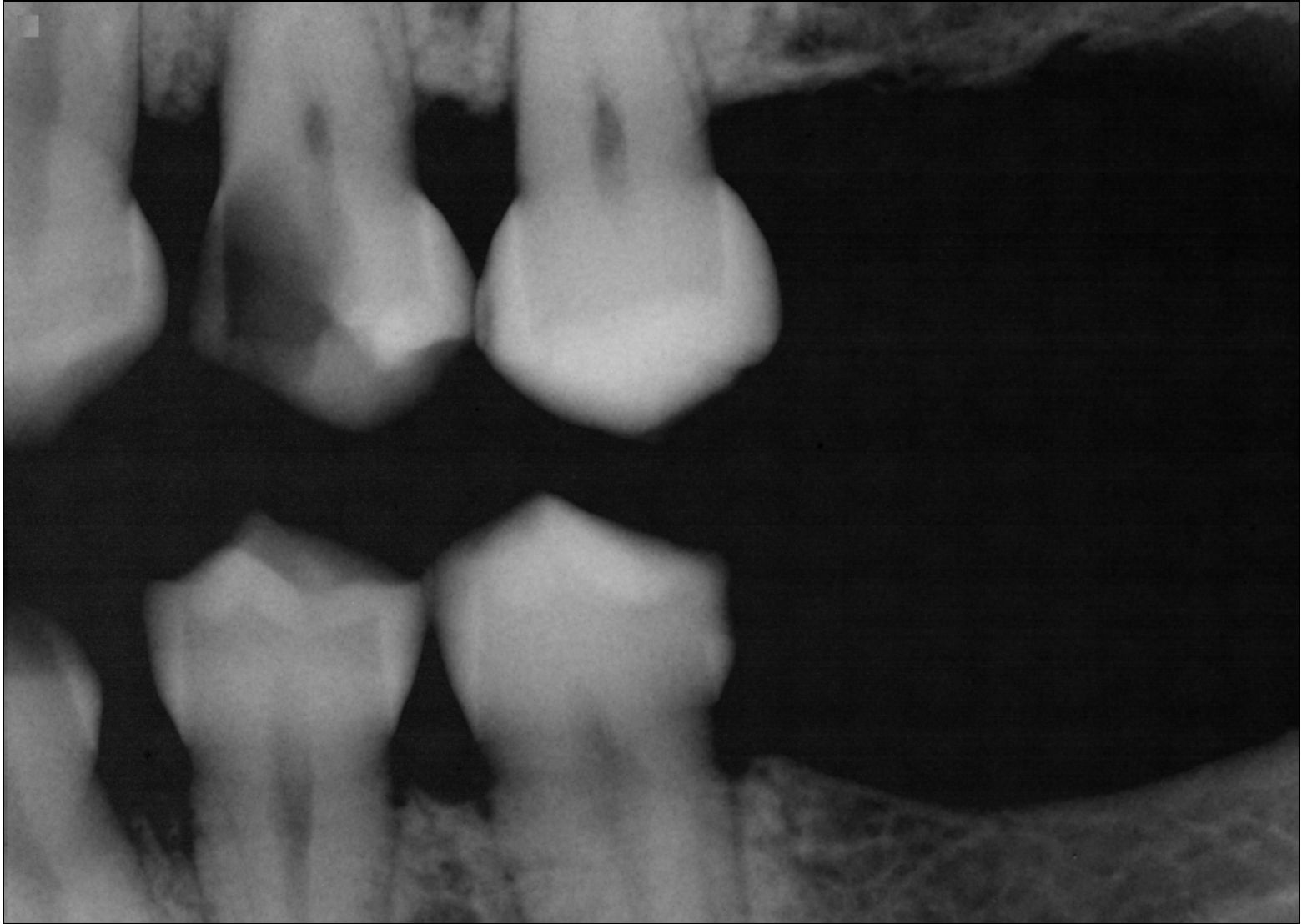
Mandibular Right Lingual View



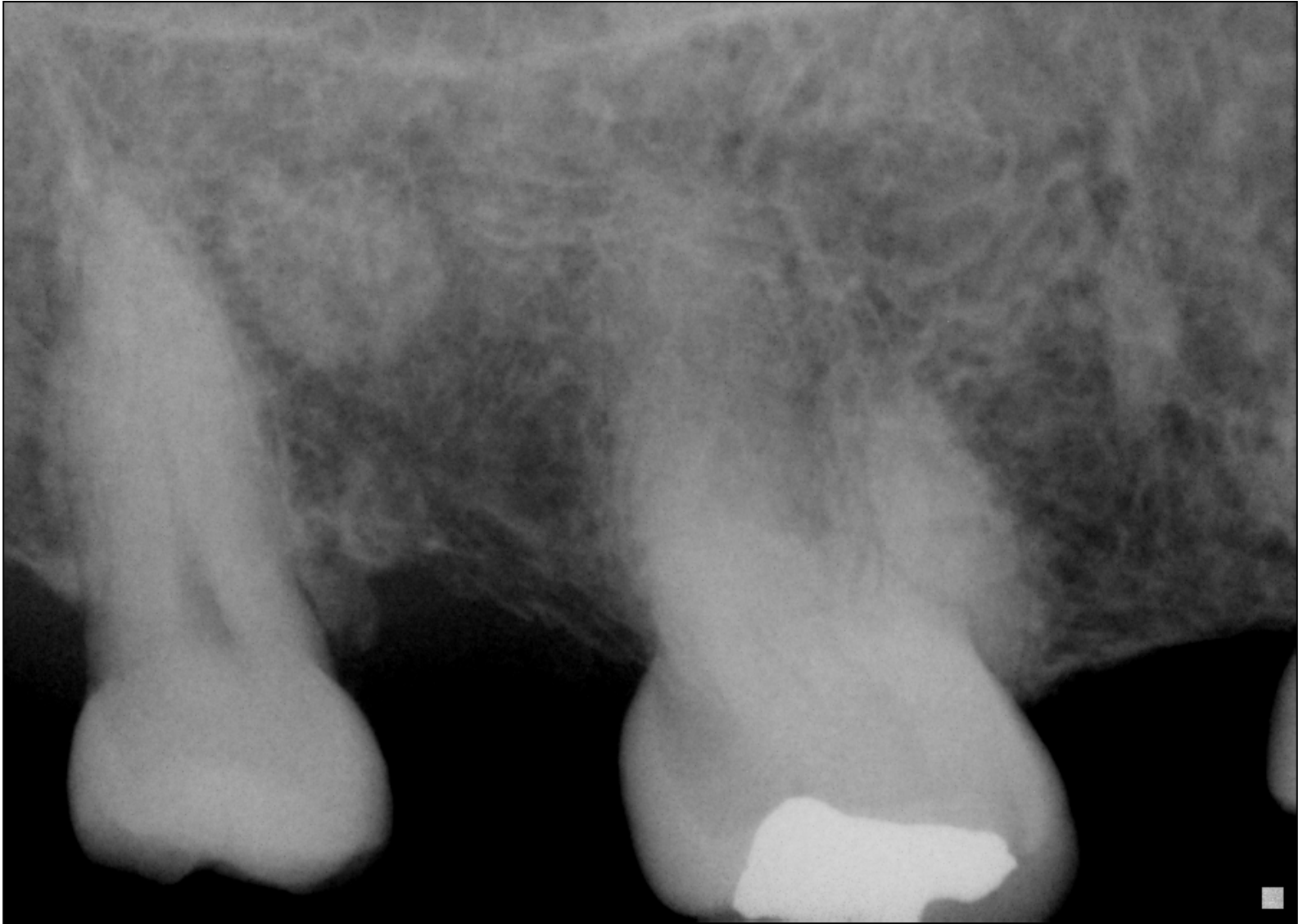PANORAMIC



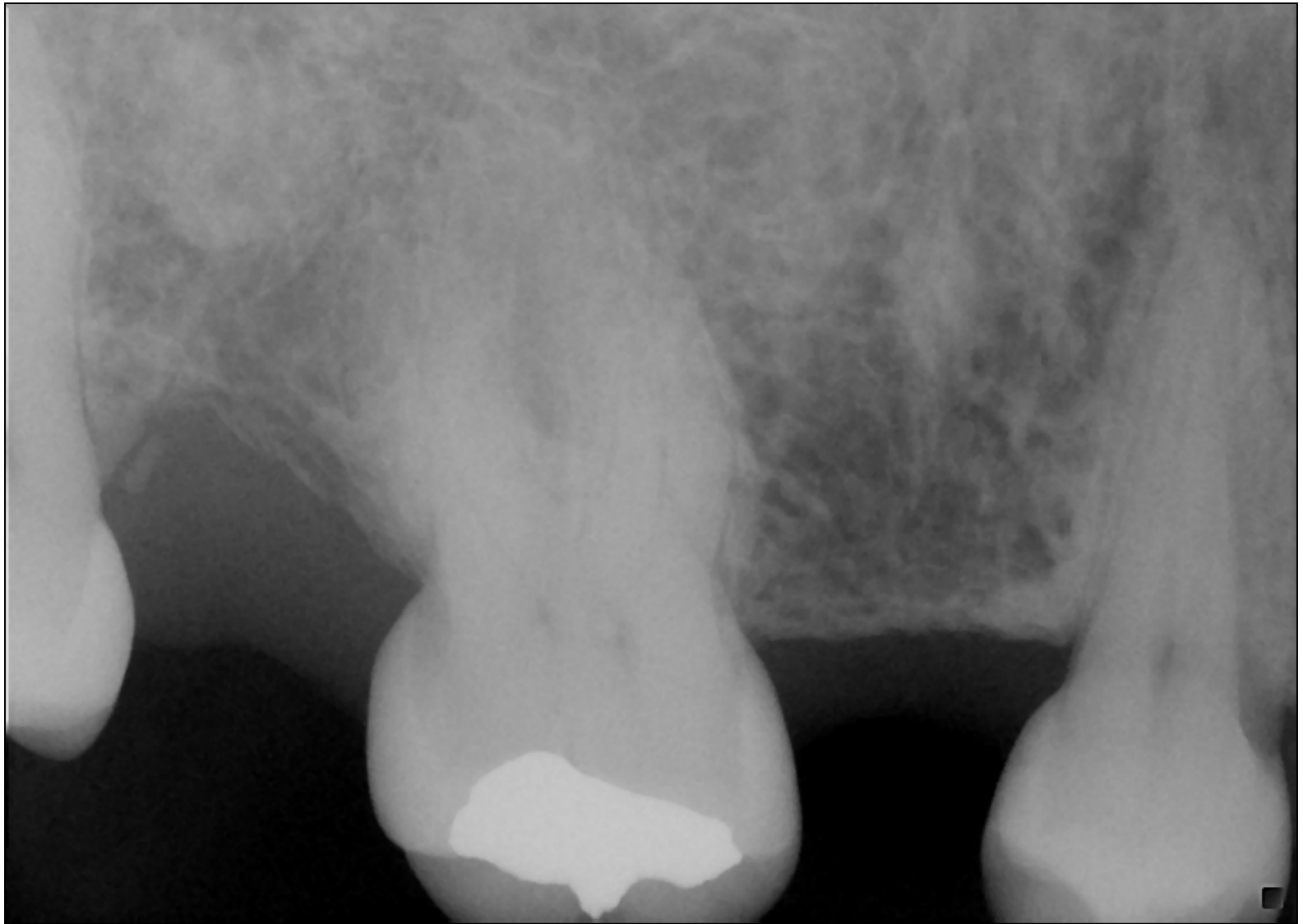RIGHT SIDE



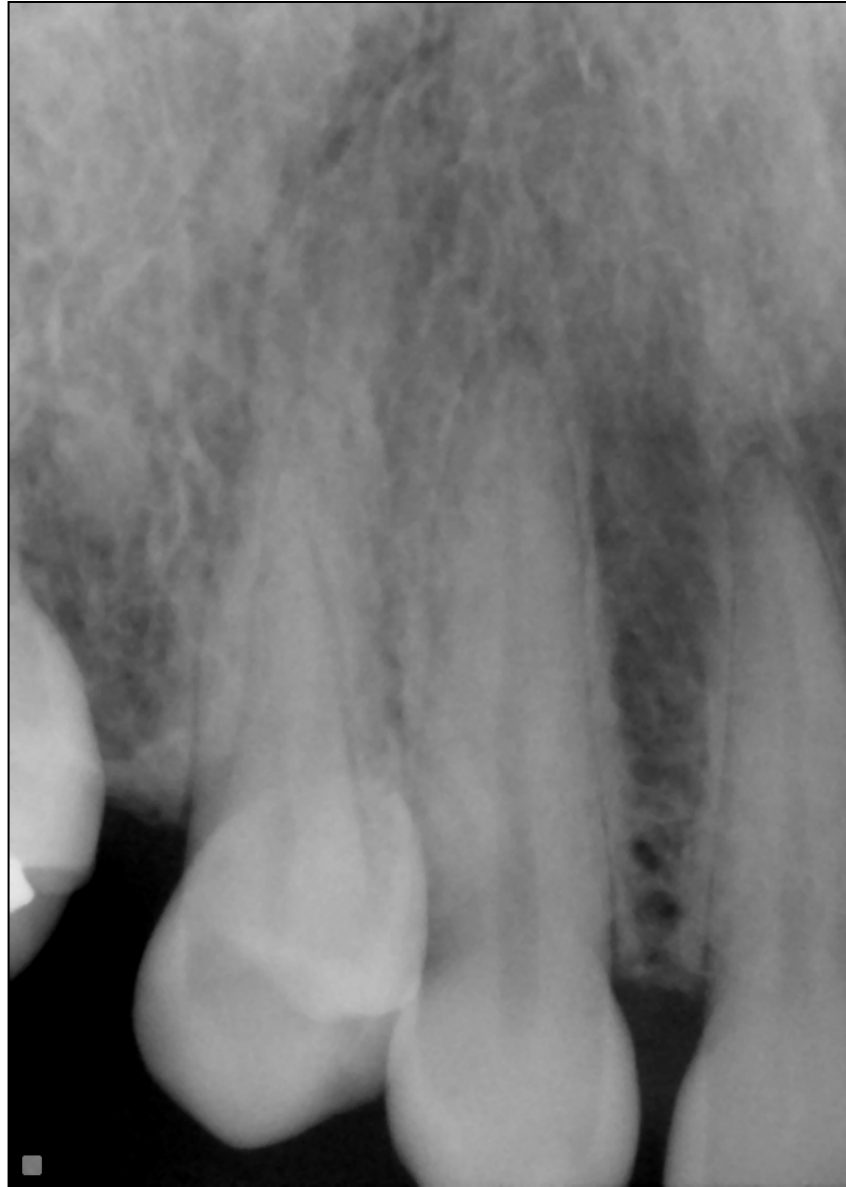LEFT SIDE



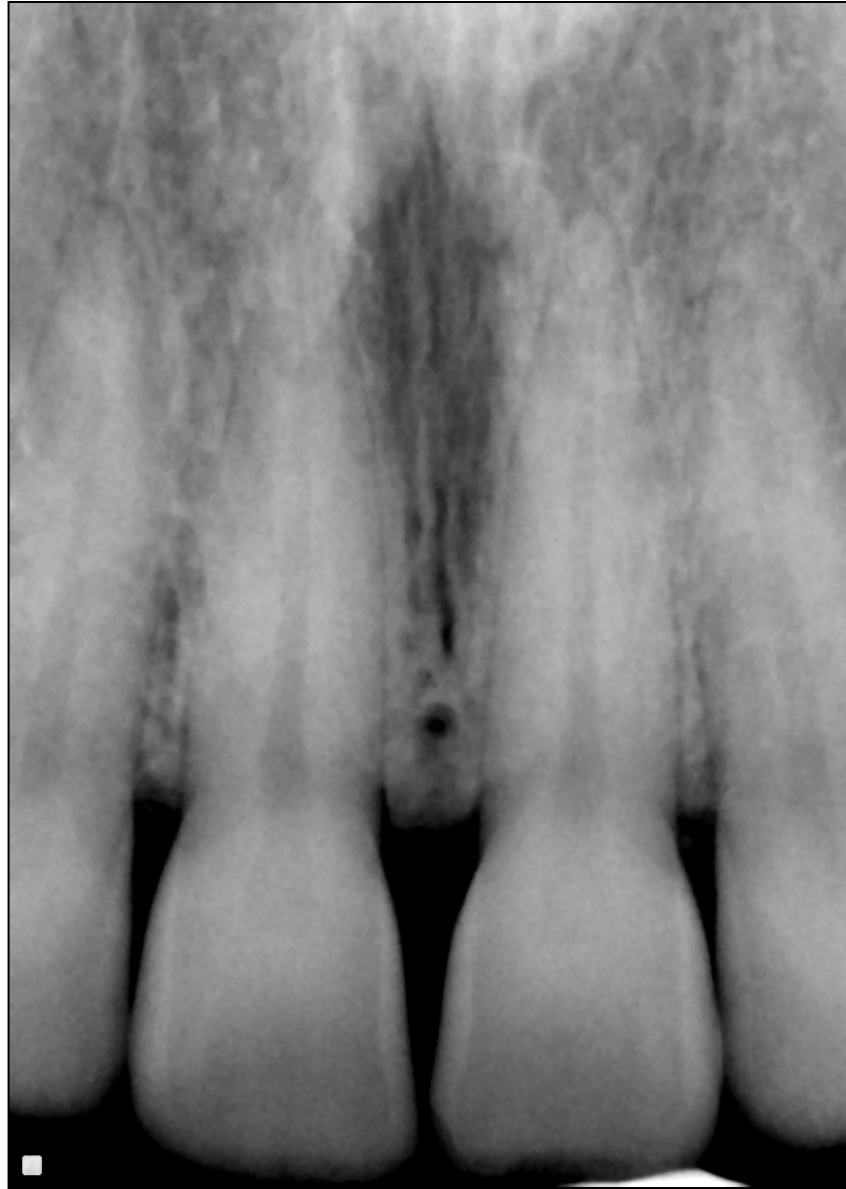MAXILLARY RIGHT



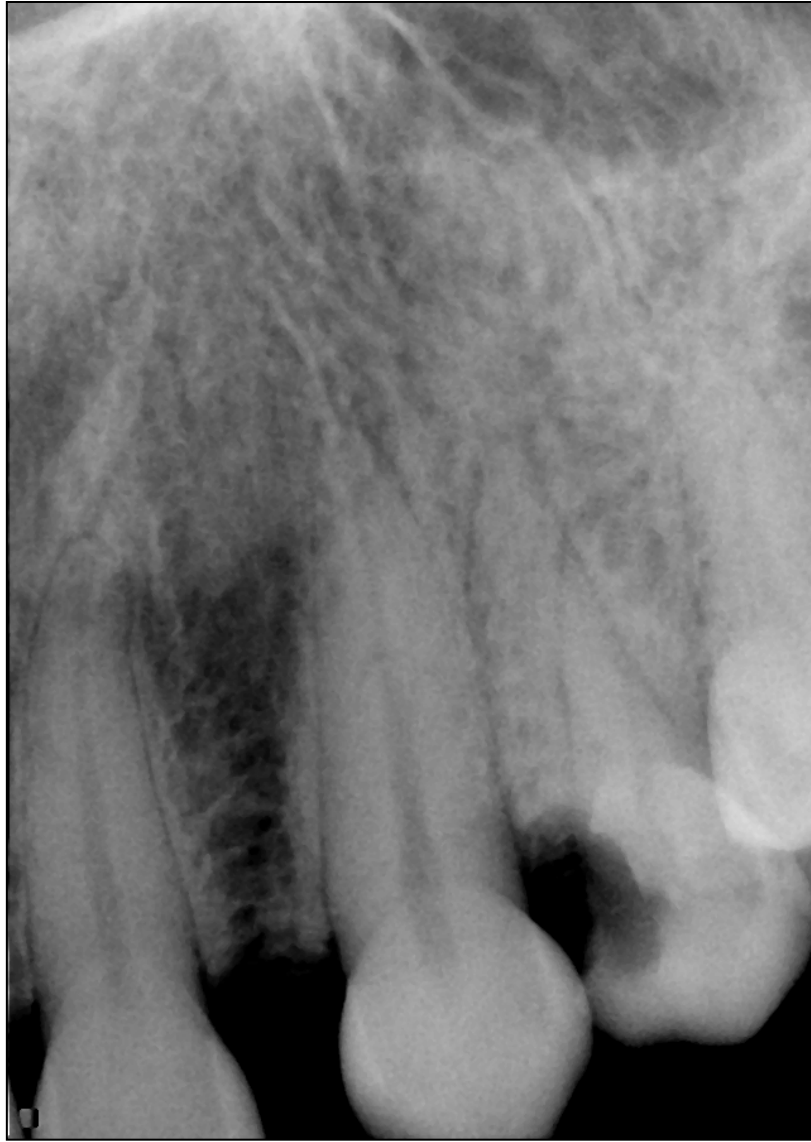MAXILLARY RIGHT



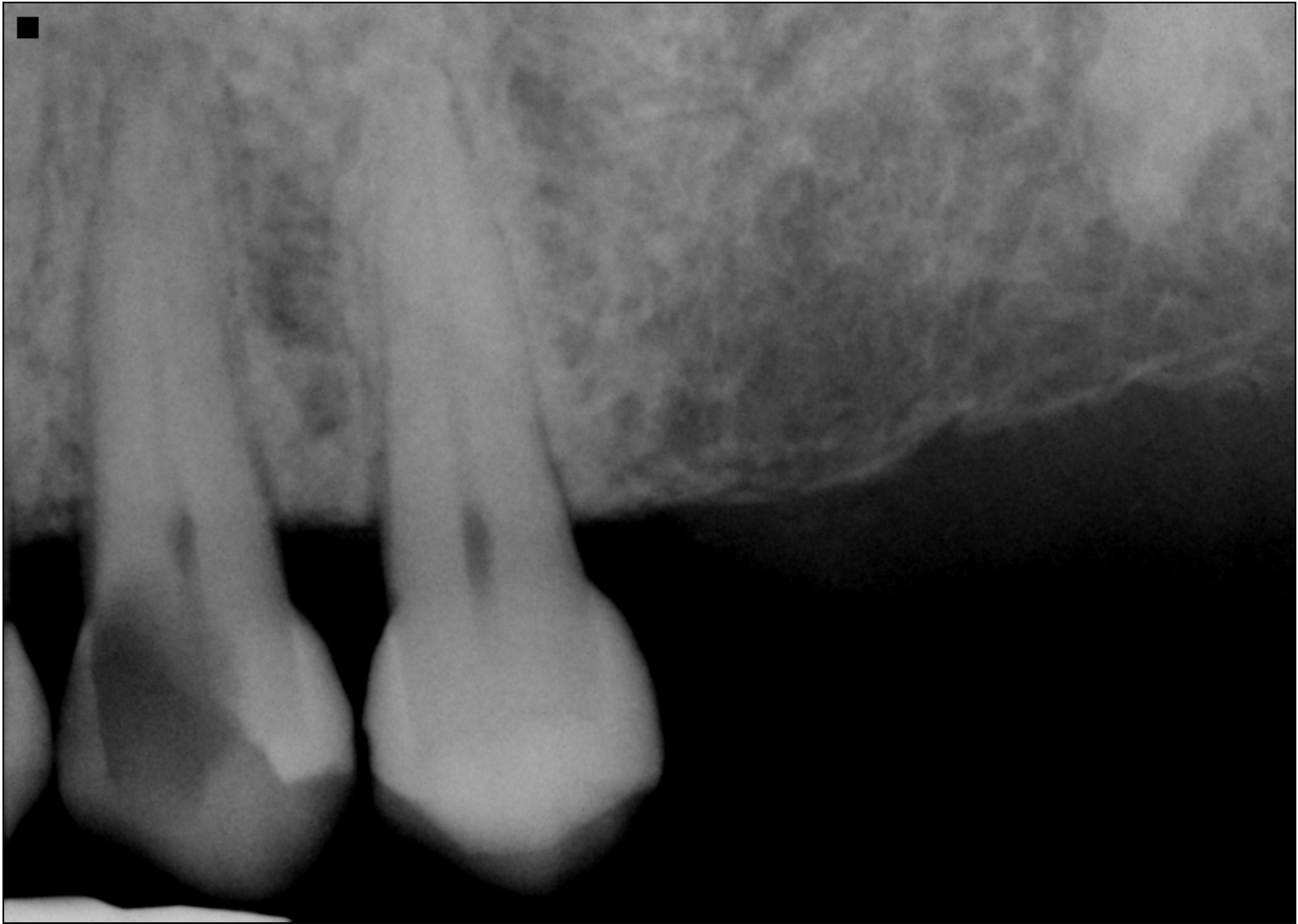MAXILLARY ANTERIOR



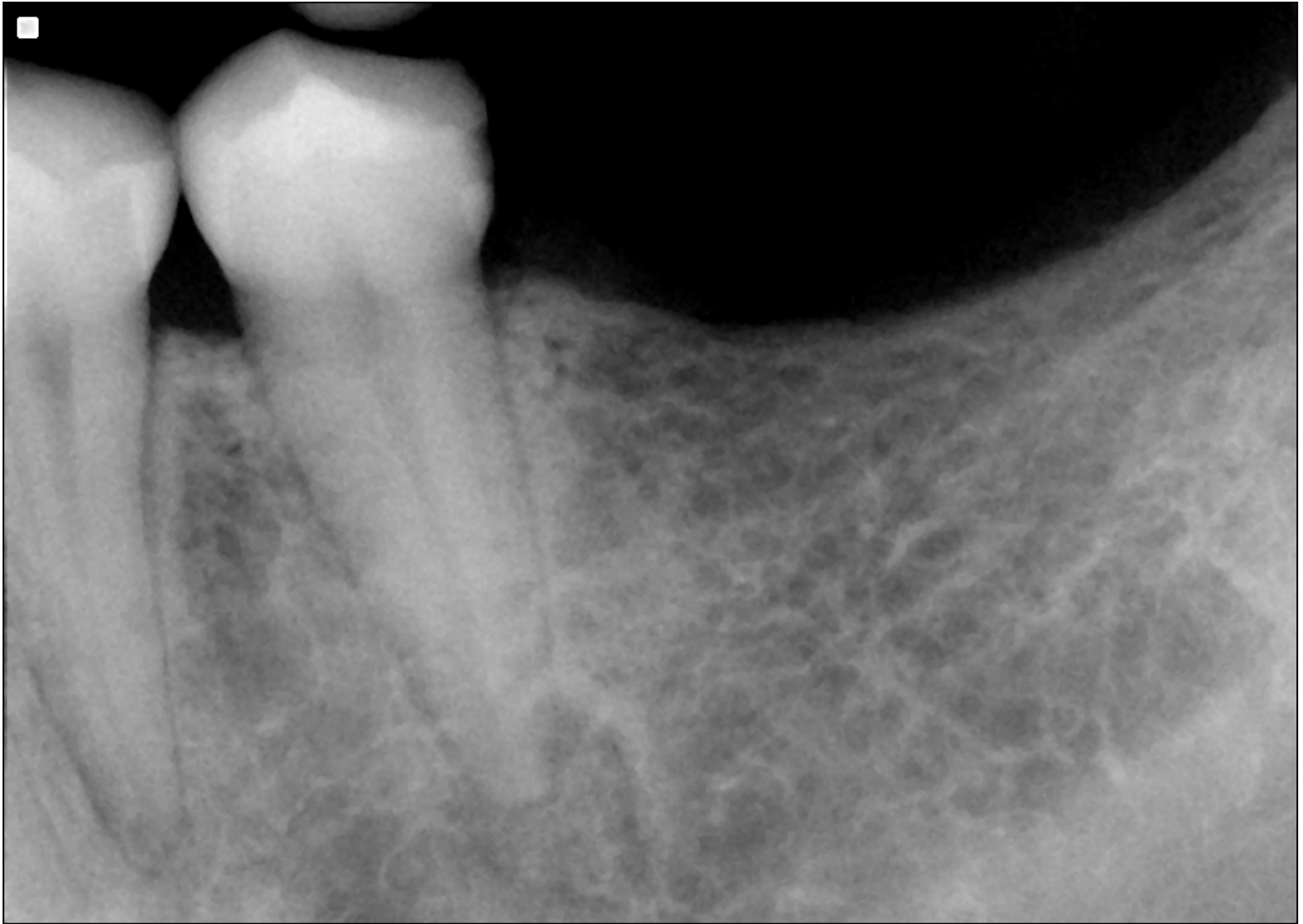MAXILLARY ANTERIOR



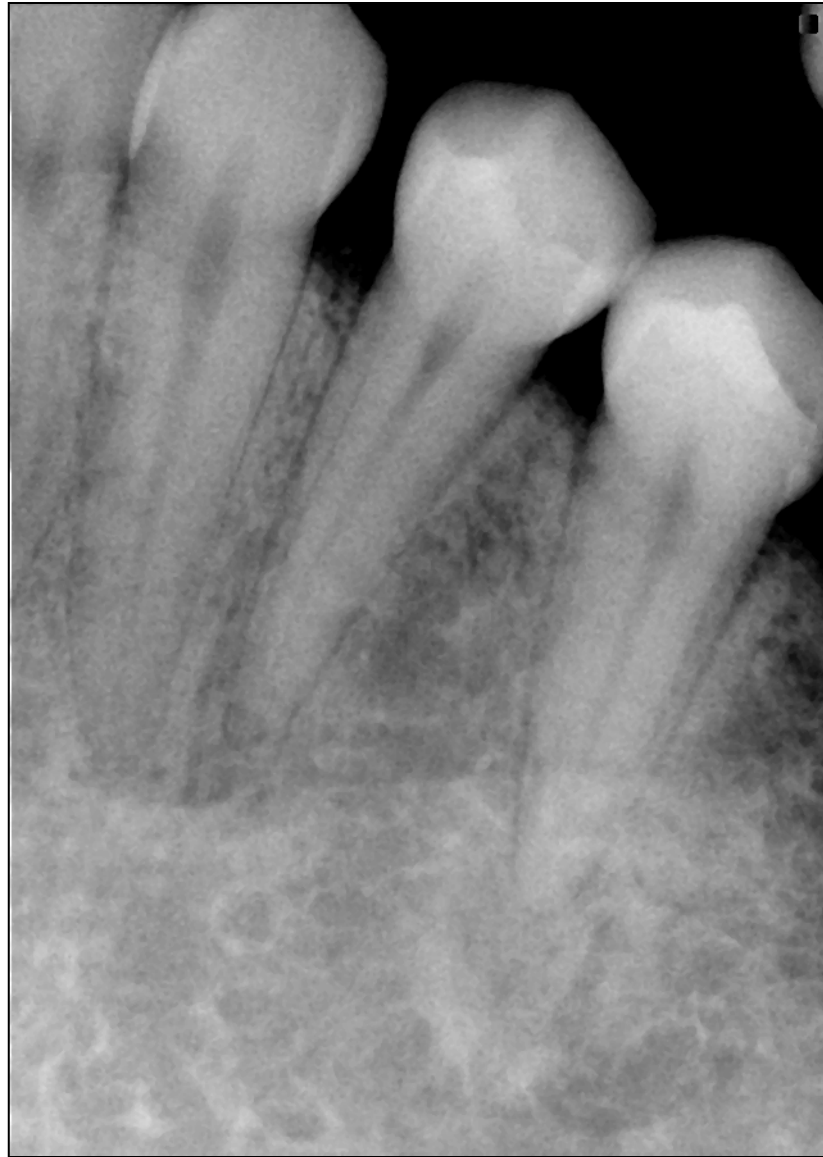MAXILLARY ANTERIOR



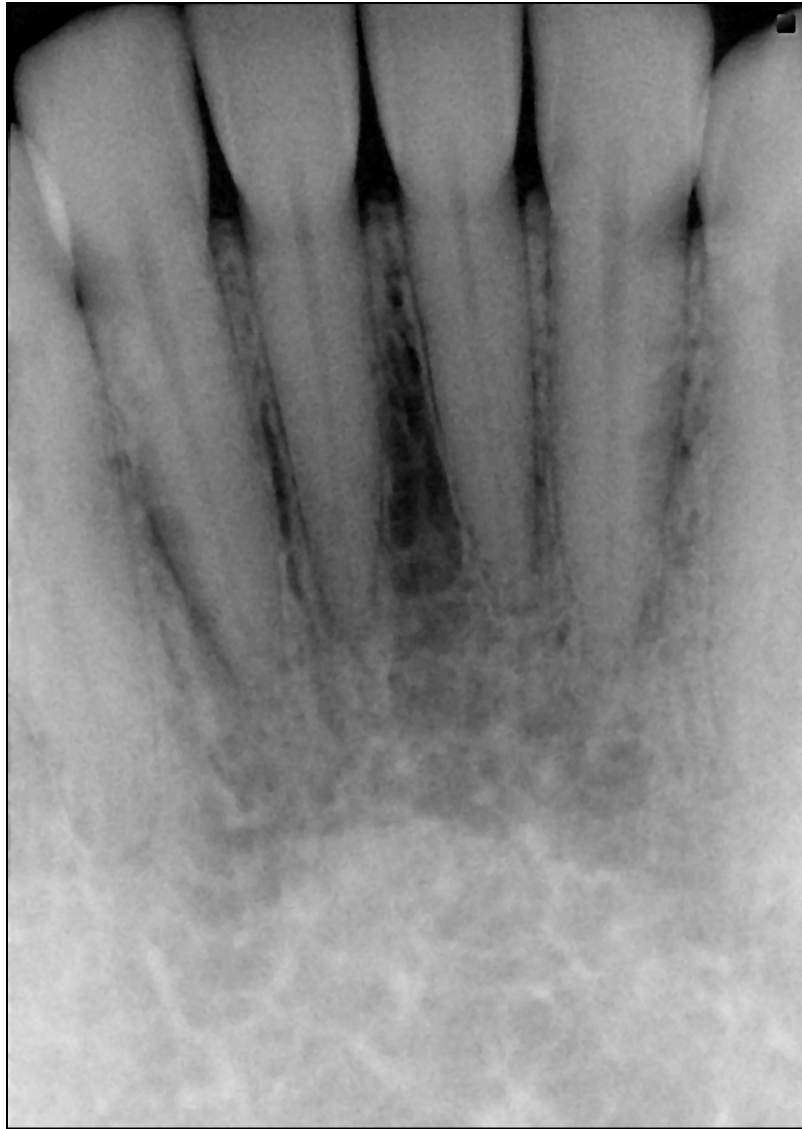MAXILLARY LEFT



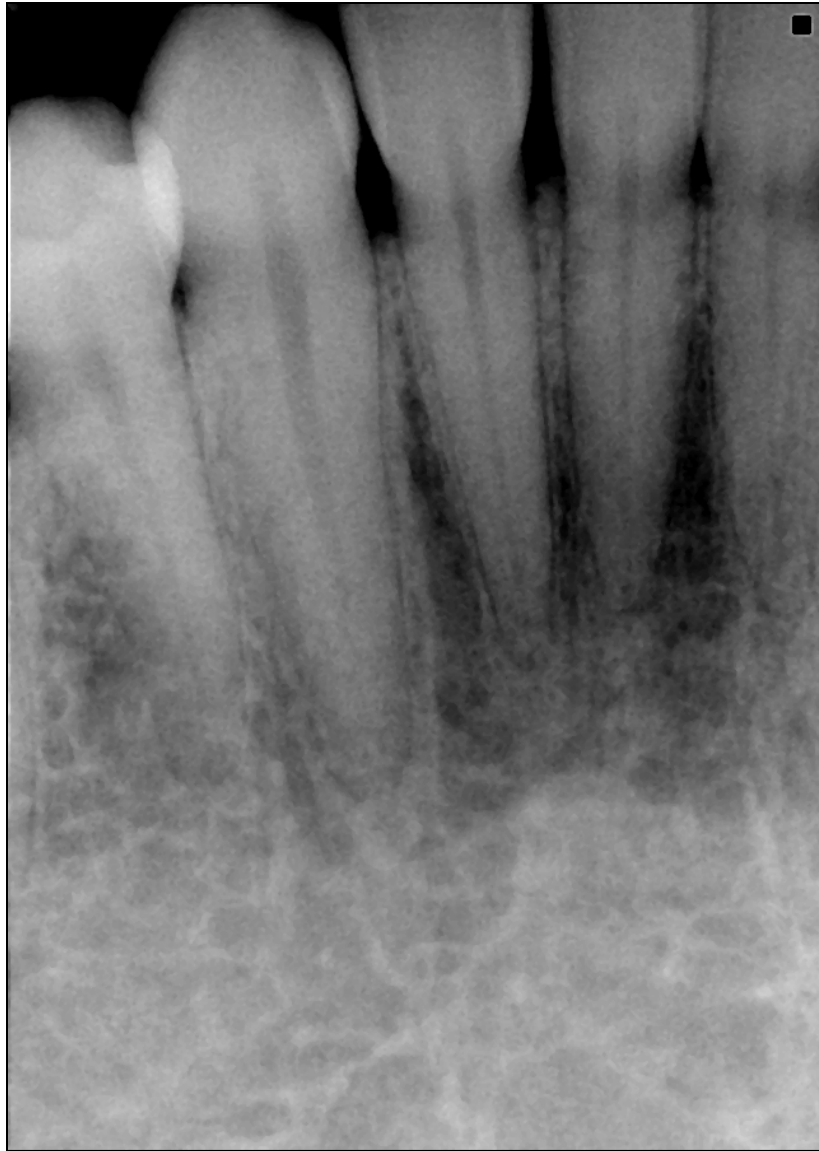MANDIBULAR LEFT



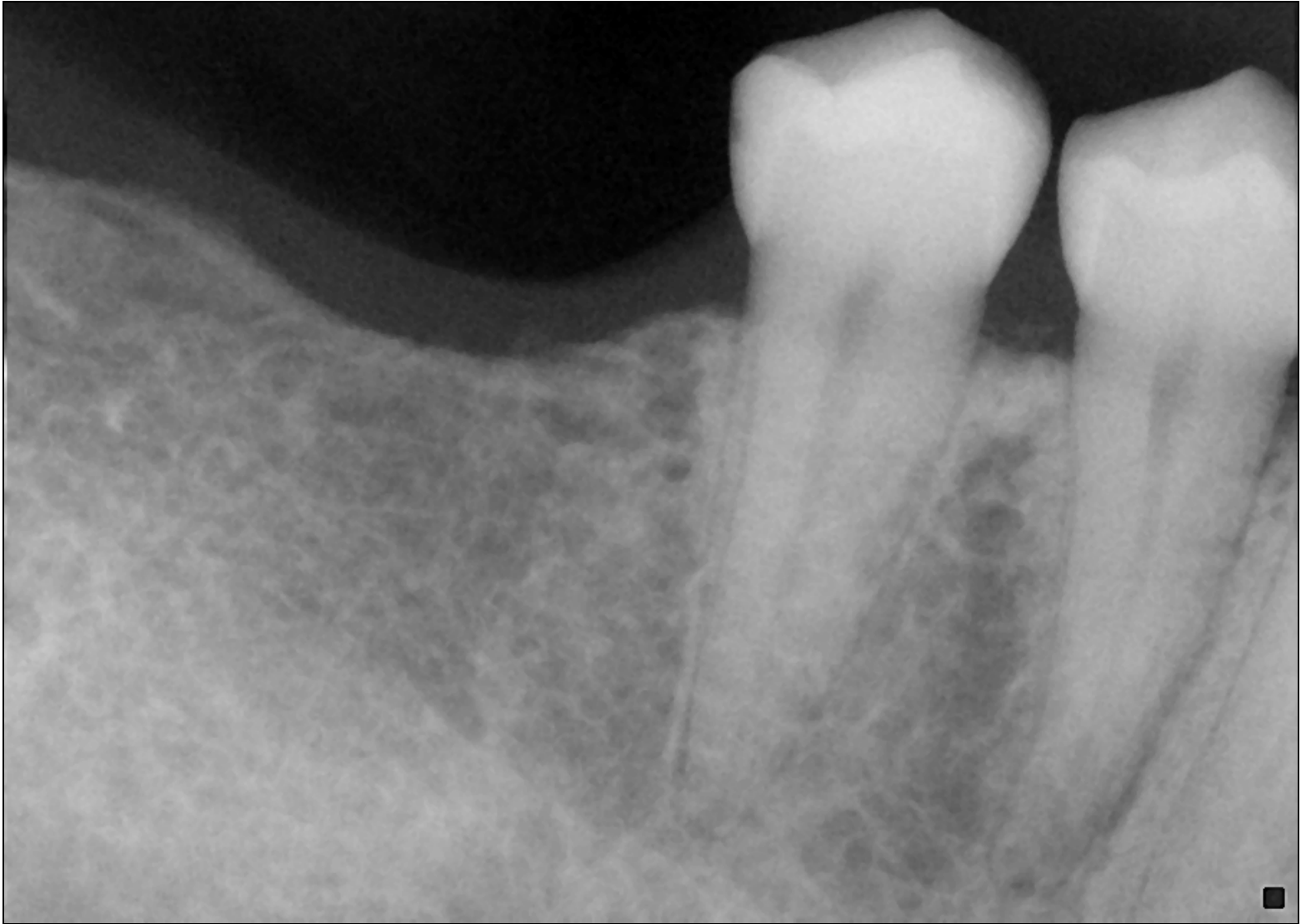
MANDIBULAR ANTERIOR



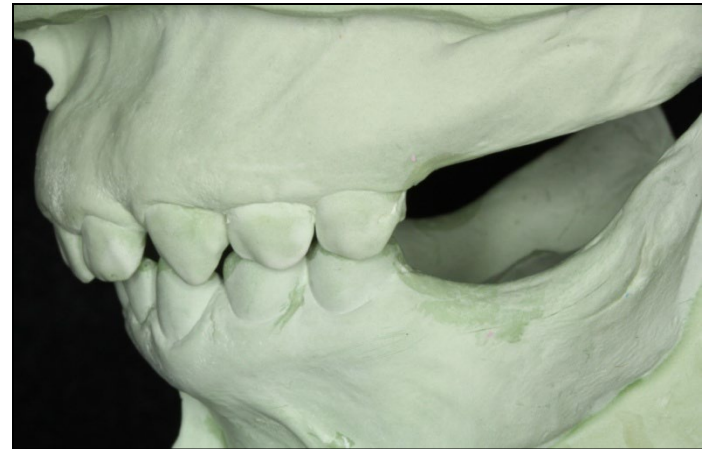
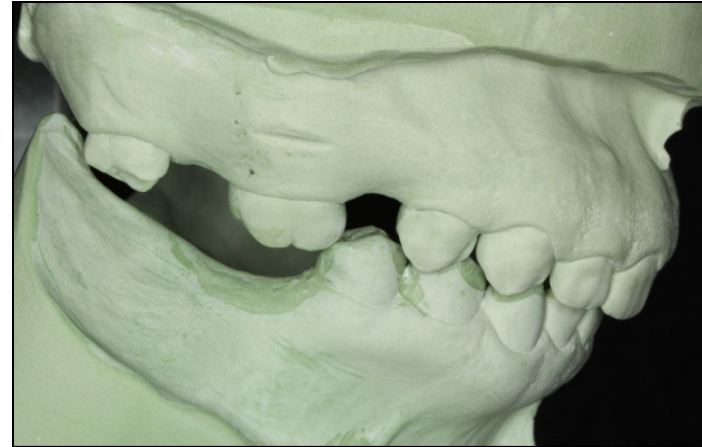MANDIBULAR ANTERIOR



MANDIBULAR ANTERIOR



MANDIBULAR RIGHT



CAST IMAGES

1 set of mounted and 1 set of unmounted models/casts will be available during the review and examination